

Four-Quadrant Approach to Capsulolabral Repair: An Arthroscopic Road Map to the Glenoid

Shane T. Seroyer, M.D., Shane J. Nho, M.D., M.S.,
CDR Matthew T. Provencher, M.D., MC, USN, and Anthony A. Romeo, M.D.

Abstract: Advancing technology, improved instrumentation, and a desire to address intra-articular pathology with a minimally invasive approach have driven the expansion of arthroscopic shoulder surgery in the past 2 decades. Proponents cite greatly improved visualization, lack of the need to perform a capsulotomy, fewer subscapularis issues postoperatively, and improved access to the entire glenohumeral joint. Our understanding and recognition of glenohumeral joint pathology have improved, and our ability to appropriately treat it has also improved. Aside from the anteroinferior and superior capsulolabral injury, orthopaedic surgeons have encountered and are able to address combined lesions, posterior labral tears, 270° to 360° labral tears, capsular laxity, humeral avulsion of the glenohumeral ligaments, associated glenoid or humeral bone loss, and partial-thickness rotator cuff tears. To adequately address the extent of pathology encountered in a shoulder instability case, access to the inferior, posteroinferior, and posterior aspects is necessary. In this technical article we present a simplified approach using safe access points by dividing the glenohumeral joint into 4 quadrants that allows for ease of instrumentation and implant placement. This will provide a blueprint for the treatment of capsulolabral injuries. In addition to portal selection and location, we will discuss several instruments we believe are advantageous in tissue manipulation and suture management.

Shoulder arthroscopy can be performed with the patient in either the beach-chair or lateral decubitus position. The major advantage of the lateral po-

sition is that through balanced suspension, access to the inferior and posterior aspects of the glenohumeral joint is optimized. Thus we prefer to perform glenohumeral arthroscopy with the patient in the lateral position. The patient is placed on a beanbag, with his or her torso rolled 30° posteriorly to position the glenoid parallel with the floor. All bony prominences are padded. An axillary roll is placed under the torso just distal to the axilla to protect the brachial plexus. After standard, sterile preparation and draping, the arm is placed in a commercially available foam sleeve, and dual balanced suspension is provided. The arm is placed in 45° of abduction and 15° of forward flexion. Ten pounds of distal suspension and ten pounds of lateral suspension are routinely used. A skin marker is used to denote pertinent bony anatomic landmarks and proposed portals, and preoperative anesthetic is injected.

With the patient in the lateral decubitus position,

From the Section of Shoulder and Elbow Surgery, Division of Sports Medicine, Department of Orthopedic Surgery, Rush University Medical Center (S.T.S., S.J.N., A.A.R.), Chicago, Illinois; and Department of Orthopaedic Surgery, Division of Sports Surgery, Naval Medical Center San Diego (M.T.P.), San Diego, California, U.S.A.

The views expressed in this article are those of the authors and do not reflect the official policy or position of the Department of the Navy, Department of Defense, or the United States Government.

The authors report no conflict of interest.

Address correspondence and reprint requests to Shane J. Nho, M.D., M.S., Rush University Medical Center, 1725 W Harrison St, Ste 1063, Chicago, IL 60612, U.S.A. E-mail: sjaynho@rushortho.com

© 2010 by the Arthroscopy Association of North America. All rights reserved.

0749-8063/10/2604-9506\$36.00/0

doi:10.1016/j.arthro.2009.09.019

when the surgeon is working on the superior portions of the glenoid (from 10- to 2-o'clock position), it is advantageous to be positioned below the shoulder so that the instruments do not need to be used in a pronated position ("backhanded fashion"). Alternatively, work done inferiorly to this position on the glenoid is more easily performed when the surgeon is positioned above the shoulder. This will simplify the use of curved suture-passing devices that require rotation for use. For the sake of simplicity in this article, when describing position on the glenoid relative to the clock face, we will be referring to a right shoulder.

PORTAL PLACEMENT

Posterior Portal

Clinical examination and ancillary studies (magnetic resonance imaging) should provide the surgeon with a preoperative plan that will guide him or her to accomplish the intraoperative goals. We begin arthroscopic shoulder surgery by establishing a posterior "viewing" portal and an anterior "working" portal.

The posterior portal is established blindly, by use of the posterolateral corner of the acromion as the anatomic landmark.¹ In a practice with a high volume of instability, this utilitarian portal needs to be located in a position to facilitate access to the posterior glenoid. If one is using lateral decubitus patient positioning, the often described posterior portal placement of 2 cm inferior and 1 cm medial to the posterolateral corner of the glenoid may leave the surgeon too medial. This will make access to the posterior glenoid at the proper oblique angle for anchor insertion difficult, making capsulolabral surgery technically more challenging. Thus we establish this portal slightly more lateral than typically described; it is established nearly in line with the lateral edge of the acromion, about 1.5 to 2 cm inferior to the most posterolateral tip. In patients with excessive soft tissue, the "Romeo 3-finger shuck" can be used to assist in localizing the joint line and optimizing portal placement.² To do this, the surgeon, using the hand that corresponds to the operative extremity (e.g., for a left operative shoulder, the surgeon performs the maneuver with his or her left hand), places the middle finger over the coracoid process and the index finger in the notch located directly posterior to the acromioclavicular joint and anterior to the scapular spine. The thumb can then be used to feel for the soft spot in the interval between the infraspinatus and the teres minor. The hand is then used to "shuck" the joint in an anterior-to-posterior direction, allowing

determination of the joint line through tactile feedback from the thumb.

Anterior Portal

The anterior portal^{3,4} is established next. This portal will serve as the initial working portal. This and all additional portals will be established by use of outside-in needle localization, to provide the optimal intra-articular position for approach to areas of injury. This portal will be slightly adjusted based on the operative plan. Initial diagnostic arthroscopic evaluation will confirm the anticipated surgical endeavor. If superior labral pathology (SLAP lesion) is present, the anterior portal will be shifted to the superior aspect of the rotator interval to facilitate instrument manipulation over the biceps tendon for suture passage and provide access to the capsulolabral tissue posterior to the biceps anchor (11 o'clock). Alternatively, if anterior or anteroinferior pathology is present, the anterior portal is shifted slightly inferior, just above the rolled upper border of the subscapularis. This will allow a more direct approach to the 2- and 3-o'clock positions of the glenoid and capsulolabral complex for anchor placement and suture passage.

Accessory Portals

The decision regarding further portal placement is dictated by the location of the pathology encountered intraoperatively. The surgeon should be able to freely adjust the preoperative surgical plan based on intraoperative findings. The addition of quadrant-specific portals allows this adaptability. Portal placement must be contemplated and executed with a global surgical plan in mind and must satisfy several considerations. They should be strategically placed to avoid crowding inside the joint, facilitate access to all 4 quadrants of the glenoid surface, minimize trauma to the encapsulating soft-tissue structures, and allow for ease of working outside the joint. They must also be established with consideration of the following: the extent of visualization, the angle of approach to allow for anchor fixation into the glenoid, the proper working angle to execute suture passage for labral fixation and capsular shifts, and cannula positioning to facilitate suture management and knot tying. Although general descriptions can be made of the standard locations of portals based on external landmarks, it must be emphasized that these locations are only estimates. Patient size, anatomy, and specific pathology constantly dictate minor variations in the cutaneous locations of our portals. In addition to securing the proper location

of entry into the joint, spinal needle localization also affords the surgeon the capability of evaluating the potential trajectory to areas of the glenoid and capsule that need to be addressed. The surgeon must be mindful of the musculotendinous and neurovascular structures at risk with portal placement.

It is advantageous to be familiar with the instruments of choice because many instruments have various inherent curvatures, which will inhibit their use through certain smaller-diameter cannulas. Furthermore, if a surgeon prefers to prepare the glenoid bone with a bur or a particular instrument, cannula placement should anticipate the necessary diameter for instrument passage.

It is preferable to use cannulas in portals that are established in intramuscular planes, minimizing soft-tissue damage. When intramuscular planes are not possible, the portal can be established and instruments can be passed percutaneously, without the use of a cannula, to protect the soft tissues. For instance, the 5-o'clock trans-subscapularis portal⁵ can be used to place anchors from the 3-o'clock to 5:30 position on the glenoid, as well as for suture shuttling, but can be performed without the use of a cannula, preventing iatrogenic damage of the subscapularis tendon. The drill guide or suture-passing devices can be inserted into the portal, and then under direct visualization, they can be used to puncture through the tendon and joint capsule at the appropriate position, with very minimal damage to the tendon. We routinely make use of the Port of Wilmington portal⁶ for posterosuperior injuries and an anterosuperolateral portal for superior capsulolabral work.⁷ The 7-o'clock portal^{8,9} is used for posteroinferior injuries as well as access to the capsule in the 5- to 6-o'clock area for suture shuttling in anteroinferior injuries. The 5-o'clock portal is used for anteroinferior work.

Conceptualizing the glenoid and labrum as a 4-quadrant grid is a fluid and simplistic way to approach any injury to the capsulolabral complex. Complex capsulolabral injuries involving more than 1 quadrant simply require the surgeon to use the tactical approach to each quadrant to easily manage the pathology. Mastery of specific portals to allow access to each quadrant is an essential component of the shoulder arthroscopist's armamentarium. Once unrestricted access to the affected zone of injury is achieved, repair becomes a simple exercise in arthroscopic surgery.

Five-O'clock Portal

The 5-o'clock portal is located approximately 2 cm inferior and slightly lateral to the standard anterior portal. It provides access to the anterior and anteroinferior glenoid and labrum. Needle localization allows the portal to be placed in the most appropriate position to provide linear access to the anteroinferior glenoid. The joint is entered at the junction of the middle and distal one third of the subscapularis tendon. This is located proximal and medial to the anterior humeral circumflex vessels. The portal is lateral to the musculocutaneous nerve and superolateral to the axillary nerve. The cephalic vein is a mean of 9.8 mm lateral to this portal.⁶ Because we do not use this portal for knot tying and because of its intratendinous location, a cannula is not required. Drill guides for anchors and suture-passing instruments are placed through this portal in percutaneous fashion, which requires only a 3- to 4-mm percutaneous incision and stab through the subscapularis tendon.

Seven-O'clock Portal

One of the most useful portals for access to important areas of pathology in the glenohumeral joint is the 7-o'clock, or posterolateral, portal. The 7-o'clock portal is established to access the posteroinferior glenoid, as well as for suture passing in the posterior quadrant and anteroinferior capsule to perform an anteroinferior capsular shift. This portal is typically located 3 cm inferior and 1 cm lateral to the posterolateral corner of the acromion. It enters the joint through the teres minor tendon at a relative safe distance of 39 mm from the axillary nerve and 29 mm from the suprascapular nerve.^{8,10} This is the only intratendinous portal that we routinely cannulate. Its strategic location makes it very appealing for knot tying and suture management, rendering cannula placement advantageous. Similar to the 5-o'clock trans-subscapularis portal, the posterolateral (7-o'clock) portal may also be used percutaneously to place suture anchors.

Port of Wilmington

The Port of Wilmington portal¹¹ is located approximately 1 cm lateral and 1 cm anterior to the posterolateral corner of the acromion. It is ideal for access to the posterosuperior region of the glenoid (10 to 11 o'clock). Because this portal is within the infraspinatus tendon and is used only for anchor placement, a cannula is not used.

FIGURE 1. Superior quadrant. SLAP tears between 2 and 10 o'clock are accessible through 1 of 3 portals: anterior portal (AP), anterosuperior lateral portal (ASL), or Port of Wilmington (PW). A cannula is generally placed in the anterior portal as well as the anterosuperior lateral portal depending on the suture-passage technique. The Port of Wilmington portal penetrates the infraspinatus and is accessed percutaneously.

FOUR-QUADRANT APPROACH TO GLENOID

Superior Quadrant

The need for access to the superior labrum for SLAP repair is common to the shoulder arthroscopist (Fig 1). Depending on the extent and type of SLAP lesion (type IIA to IIC),¹¹ the arthroscopist should be able to easily access the glenoid-labrum complex both anterior to the biceps (1 o'clock) and posterior (11 o'clock). If the pathology is in the superior quadrant, the standard anterior portal is placed more superiorly in the rotator interval to allow instruments to maneuver over the biceps tendon to enable access to the posterosuperior labrum for suture placement and management. An 8.25-mm cannula is placed in the anterior portal (as opposed to a standard 6-mm cannula) to allow passage of the curved suture-passing device that we use to pass sutures through the labrum in the 11-o'clock position. A smaller cannula will "capture" this instrument and inhibit us from having the access and

soft-tissue manipulation we desire. Depending on the configuration of the SLAP tear, we usually use 1 or 2 anchors; the first is usually just posterior to the biceps root, with another more posterior if necessary (11:30 and 11-o'clock positions). If the labrum is truly detached anterosuperiorly, we will also consider an anchor in this location. For anchor placement, we approach the glenoid through the anterosuperolateral portal.⁶ Alternatively, many surgeons elect to use a Neviaser portal for anchor placement.¹² This portal is located just medial to the triangle formed by the junctions of the posterior aspect of the clavicle, the acromion, and the anterior portion of the scapular spine. The angle of approach from this portal is parallel to the glenoid face and increases the risk of penetration of the subchondral surface of the glenoid surface. When done carefully, it does, however, provide a viable option for SLAP repair. In our hands, the anterosuperolateral portal allows a better angle of approach to the rim of the glenoid, providing us with the optimal 45° angle of entry into the glenoid rim with the anchor. Because this portal is used for anchor placement only, a cannula is not necessary. The drill guide can be inserted percutaneously through the portal, and the desired location for capsular perforation can be selected with direct intra-articular visualization. To simplify suture management, we place the anchor and secure the knot to this anchor before proceeding to the next anchor. To pass suture through the capsulolabral structures at the 1-o'clock position, a straight instrument with an inline curve—for instance, a crescent (Spectrum; Linvatec, Key Largo, FL)—allows a direct approach because it is in line with the anterior cannula placement. To pass sutures posterior to the biceps anchor, a suture-passing device with a 45° or 60° curved tip is used. In a left shoulder we will use a device with a curve to the right; in a right shoulder, it is advantageous to use a device that will pass suture with a curve directed to the left. The device is inserted through the cannula in the anterior portal and directed over the biceps tendon to access the posterosuperior labrum while viewing from the posterior portal. Special attention is directed to placing the knot on the posterior surface of the labrum to prevent potential abrasion of the humeral head. The sutures are retrieved and tied through the anterior portal. The superior placement of this portal in the rotator interval allows the knot pusher to maneuver above the biceps to access the anchor.

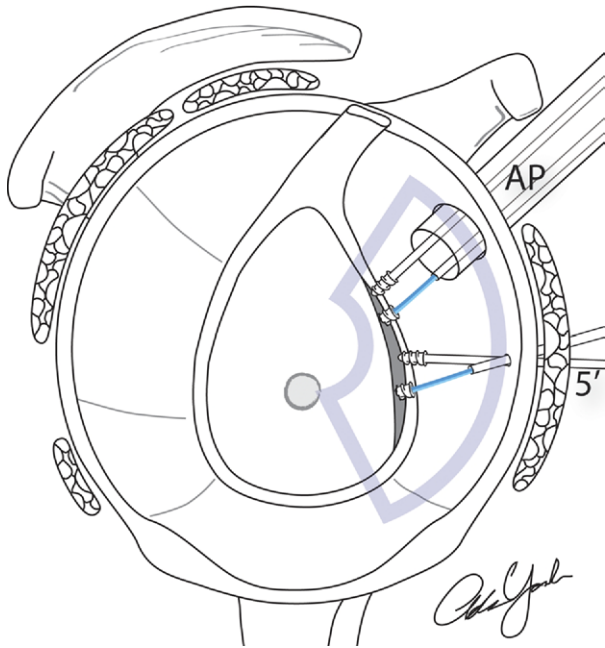


FIGURE 2. Anterior quadrant. Anterior and anteroinferior labral tears are accessible through the anterior portal (AP) and 5-o'clock portal (5'). The 5-o'clock portal is placed through the junction of the middle and inferior one third of the subscapularis tendon, and use of a cannula is avoided to minimize injury to the subscapularis tendon.

Anterior Quadrant

The approach to the anterior quadrant becomes important for anterior work in type IIA and IIC¹¹ or type V through VII SLAP lesions,⁶ as well as the superior extent of Bankart lesions and access to the subscapularis (Fig 2). Although this quadrant is not frequently used for glenoid anchors, it allows a direct approach to the capsule and labrum with suture-passing devices and anchor-drilling guides. To place anchors in the 1- and 2-o'clock positions of the glenoid, the drill guide and anchor can be inserted through this modified anterior portal and have a direct approach to these locations. Below the 2-o'clock position (2:30 to 4 o'clock), the 5-o'clock portal can be used for anchor insertion into the glenoid. As mentioned previously, to avoid iatrogenic trauma to the substance of the subscapularis, a cannula is not used in this portal. Suture passing through the capsulolabral complex at the 3- to 4-o'clock position is routinely done with a curved-tip (45° or 60°) suture-passing device inserted through the anterior cannula. In a left shoulder the shuttling suture (polydioxanone [PDS]) is passed through the capsule and labrum by use of an instru-

ment with the tip curving to the left. Alternatively, in a right shoulder an instrument with a tip curved to the right is used to pass a lead suture through the capsule and under the labrum to allow the suture from the anchor to be passed under the labrum to enable a knot to be tied and secure the labrum.

To pass sutures through the capsule from the 1-o'clock to 2:30 position on the glenoid, we use a straight, soft tissue-penetrating, suture-passing device with a 20° to 30° curve in line with the device.

Inferior Quadrant

Anterior instability is most often associated with capsulolabral injury from the 3- to 6-o'clock position. Thus this injury must often be treated by combining the approaches to the anterior and inferior quadrants (Fig 3). Successful arthroscopic treatment of this injury has been achieved with a posterior portal for visualization during anterior repair, but the arthroscope must be periodically placed in the anterior cannula to assess bone preparation of the glenoid. To prevent recurrence, a capsular shift is included to tighten the redundant/stretched anteroinferior capsule. To do this, the surgeon must have access to the glen-

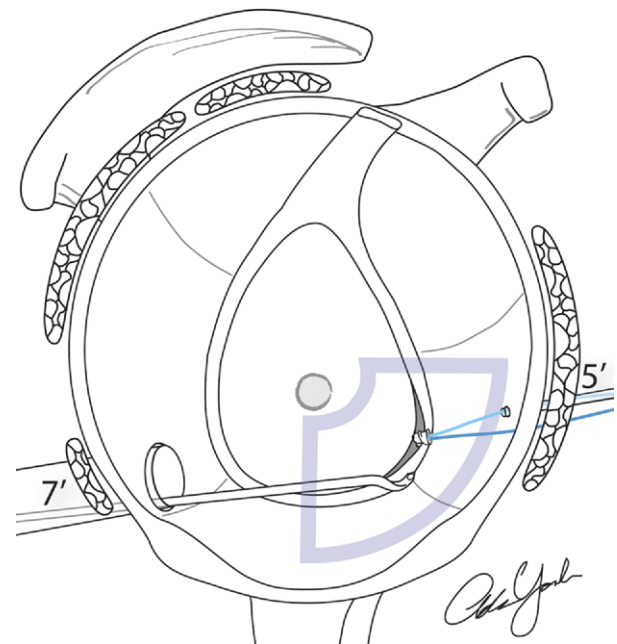


FIGURE 3. Anteroinferior quadrant. Anteroinferior capsulolabral tears are accessible through the 5-o'clock portal (5') and 7-o'clock portal (7'). We prefer to establish a 7-o'clock portal with an 8.25-mm cannula for all anteroinferior labral tears as the working portal. Suture-passing devices can be used to access the inferior half of the glenoid through the 7-o'clock portal.

noid from the 5:30 to 3-o'clock position but must be able to place sutures in the capsule as low as the 6-o'clock position to perform the capsular shift. Although this may be performed by use of suture-passing devices from the anterior (or 5-o'clock) portal, the plane of tissue that can be captured with the devices entering from these portals is not collinear with the orientation of the capsular shift. Using a curved-tip suture-passing device inserted through the 7-o'clock portal, the surgeon can capture the capsulolabral tissue in line with the desired shift. Customarily, the capsule will be imbricated starting at the ½ to 1-o'clock position distal to the location of the anchor placement (i.e., for an anchor at the 5-o'clock position, tissue should be imbricated from the 5:30 position and shifted superiorly). The 5-o'clock portal is used percutaneously to gain access to the anteroinferior glenoid for anchor placement. The lowest anchor is usually placed at approximately the 5-o'clock to 5:30 position on the glenoid. After the needle localization of the 7-o'clock portal, a switching stick is inserted through the portal to ensure proper access and trajectory. To establish the proper intra-articular trajectory, the needle should be oriented about 60° to 70° to the floor. An 8.25-mm cannula is placed in this portal, to accommodate various suture-passing devices. A curved, soft tissue-penetrating, suture-passing device is used to access the capsule and perform the shift. In a right shoulder, a device with the curved tip directed to the left is used; in a left shoulder a curved tip directed to the right is more advantageous. A PDS suture is passed through the capsule and under the avulsed labrum near the 6-o'clock position and is retrieved (along with the medial suture limb of the anchor) from the anterior portal for suture relay. After the PDS is tied to the anchor limb, this limb is shuttled through the labrum and retrieved through the 7-o'clock portal, which is then used to tie the knot. This same process is repeated for each additional anchor required. Once the 4-o'clock to 4:30 position is reached, the anterior quadrant becomes the working quadrant and the approach to the anterior quadrant is implemented for the completion of the repair.

Access to the posteroinferior glenoid, between 6:30 and 8:30, is required for reverse Bankart lesions, multidirectional instability cases, and posterior extent of anteroinferior instability past the 6-o'clock position (Fig 4). Approach to this portion of the glenoid is achieved through the 7-o'clock portal. We place an 8.25-mm cannula to allow passage of curved suture-passing instruments or a bur, if needed, to prepare a bone bed for a posterior Bankart lesion. Sutures from

anchors in this portion of the glenoid can be retrieved through the posterior cannula to ease suture management and to avoid suture tangling, because the suture-passing devices are inserted through the 7-o'clock portal to access the posteroinferior capsule to perform the necessary shift. The sutures in the 7-o'clock to 8:30 anchors are tied through the 7-o'clock portal. In extensive, complex posterior labral pathology, the inferior portion of the injury complex is addressed first. We believe that the posterosuperior shift of the posteroinferior capsule is the most vital component of the repair and should be performed first. Once this component is repaired, the reconstruction efforts can proceed superiorly to include the entire zone of injury. Once the repair has progressed to the 9-o'clock position, the surgical approach is shifted to working through the standard posterior portal, as described previously, to allow for a more direct approach to the capsulolabral tissue at that level.

Posterior Quadrant

When repairing SLAP lesions that have posterior extension (type IIB, IIC, or VIII¹³), posterior Bankart lesions, or multidirectional instability, the surgeon needs to be able to adequately access the posterior and posterosuperior labrum. Although the posterior portal

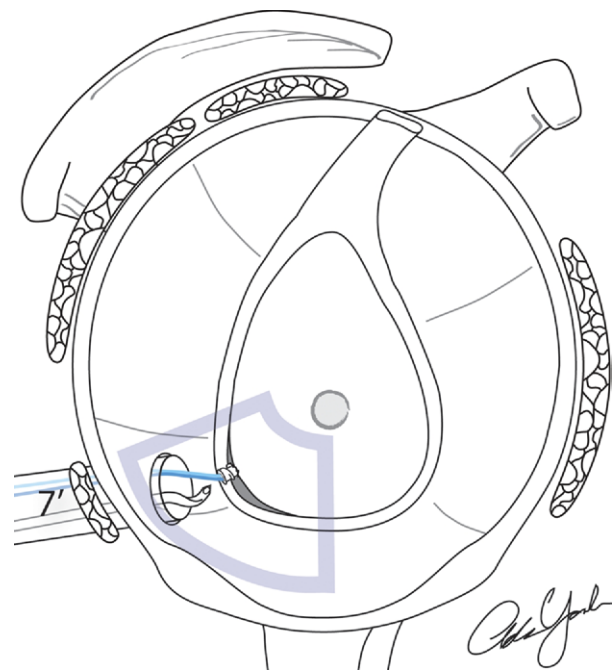


FIGURE 4. Posteroinferior quadrant. The 7-o'clock portal (7') can be used to access posterior labral tears, 270° labral tears, or 360° labral tears for anchor insertion or suture management.

is our standard viewing portal, for posterior injuries, we will switch the arthroscope to the anterior portal to provide better visualization of the posterior labrum. To access the posterosuperior glenoid for anchor placement in the 9:30 to 10:30 position, the suture anchor drill guide is placed percutaneously through the Port of Wilmington portal. A curved suture-passing device is placed through the posterior portal (curved to the right for right shoulders and to the left for left shoulders). The knots will be tied through the posterior cannula.

As the extent of the injury progresses down the posterior glenoid and labrum, the posterior and 7-o'clock portals are used for anchor placement and suture passage and management. The arthroscope remains in the anterior cannula for visualization. The extent of the patient's capsulolabral injury and the patient's clinical presentation and symptoms will dictate our approach to the capsule. If the patient has posteroinferior instability complaints and a posteroinferior capsular injury, the posterior surgery is initiated at the 7-o'clock position on the glenoid so that the tissues in the posteroinferior axillary recess can be accessed to perform a capsular shift in a posterosuperior direction. The 9- and 10-o'clock positions on the glenoid are easily accessed for anchor placement with the drill guide introduced into the joint through the cannula in the standard posterior portal. To avoid subchondral penetration of the anchors on the glenoid surface, the surgeon's hand must be almost perpendicular to the floor, once the guide is placed on the edge of the glenoid. In the 9- and 10-o'clock positions, a superior capsular shift is not necessary. The capsular plication/fixation is performed in a horizontal direction. To accomplish this, a straight suture-passing device with an inline curve to it (the same instrument used at the 2-o'clock position anteriorly) can be inserted through the posterior cannula to place the PDS suture through the capsule and labrum at the level of the anchor. Standard suture relay is then performed to deliver the suture from the anchor through the capsule and labrum. The sutures in the 9- and 10-o'clock anchors will be tied through the cannula in the posterior portal.

CONCLUSIONS

Glenohumeral capsulolabral pathology is a common entity faced by the general orthopaedist. Advances in arthroscopic techniques and instrumentation have allowed capsulolabral reconstruction to be performed entirely through an arthroscopic ap-

TABLE 1. *Pearls and Tips for Arthroscopic Management of Glenohumeral Pathology*

General tips	
	With the patient in the lateral decubitus position, the surgeon should be positioned to avoid backhanding instruments, that is, standing below the shoulder for superior glenoid-labrum work (proximal to 10 and 2 o'clock) and above the shoulder for inferior work
	Know cannula diameters required for passage of instruments of choice
	Perform outside-in needle localization to establish portals, ensuring proper access and angle of approach to glenoid and labrum
	Avoid use of cannula if possible in intratendinous locations
	Place knots on posterior surface of labrum to prevent potential abrasion of humeral head
Superior quadrant	
	Shift anterior portal to superior portion of rotator interval to allow access to capsule/labrum posterior to biceps
	Place anchors percutaneously through anterosuperolateral portal
Anterior quadrant	
	Shift anterior portal to inferior portion of rotator interval
	Establish 5-o'clock portal (no cannula) to access 3- to 4-o'clock position of glenoid/labrum
Inferior quadrant	
	Drill 4-o'clock to 5:30 anchors from 5-o'clock portal
	Establish 7-o'clock portal to access capsule in line with intended anterosuperior capsular shift
	Use suture-passing device with tip curved to left for right shoulder and curved to right for left shoulder
Posterior quadrant	
	Establish 7-o'clock portal for posteroinferior glenoid access
	Orient needle about 60°-70° to floor to establish proper intra-articular trajectory through 7-o'clock portal
	Position hand relatively perpendicular to floor (lateral decubitus) to allow proper orientation of anchor in glenoid

proach. The arthroscopist must develop a tactical surgical approach that will allow access and visualization to the entire glenoid and labrum. Adopting a 4-quadrant approach the glenoid and labrum can simplify this process and allow an effective, reproducible approach to the entire surface of the glenoid (Table 1). The approaches to the superior, anterior, posterior, and inferior quadrants can be combined to treat complex cases that involve pathology that traverses multiple quadrants. The surgeon's surgical approach should include consideration of the location of portal placement, suture management, visualization, and ability to approach necessary portions of the glenoid for anchor fixation. Percutaneous portal utilization can help prevent iatrogenic damage to soft-tissue structures that may be caused by cannulas. The detailed approach described in this article will allow the arthroscopist access to the entire glenohumeral joint and transform repair of

complex intra-articular pathology into simple exercises in arthroscopic surgical technique.

Acknowledgment: The authors thank Adam Yanke, M.D., for his illustrations.

REFERENCES

1. Andrews JR, Carson WG Jr, Ortega K. Arthroscopy of the shoulder: Technique and normal anatomy. *Am J Sports Med* 1984;12:1-7.
2. Mazzocca AD, Noerdlinger M, Cole B, Romeo A. Arthroscopy of the shoulder: Indications and general principles of techniques. In: McGinty J, ed. *Operative arthroscopy*. Philadelphia: Lippincott Williams & Wilkins, 2003;412-427.
3. Matthews LS, Zarins B, Michael RH, Helfet DL. Anterior portal selection for shoulder arthroscopy. *Arthroscopy* 1985; 1:33-39.
4. Wolf EM. Anterior portals in shoulder arthroscopy. *Arthroscopy* 1989;5:201-208.
5. Davidson PA, Tibone JE. Anterior-inferior (5 o'clock) portal for shoulder arthroscopy. *Arthroscopy* 1995;11:519-525.
6. Lo IK, Lind CC, Burkhart SS. Glenohumeral arthroscopy portals established using an outside-in technique: Neurovascular anatomy at risk. *Arthroscopy* 2004;20:596-602.
7. Laurencin CT, Deutsch A, O'Brien SJ, Altchek DW. The superolateral portal for arthroscopy of the shoulder. *Arthroscopy* 1994;10:255-258.
8. Davidson PA, Rivenburgh DW. The 7-o'clock posteroinferior portal for shoulder arthroscopy. *Am J Sports Med* 2002;30: 693-696.
9. Chhabra A, Diduch DR, Anderson M. Arthroscopic repair of a posterior humeral avulsion of the inferior glenohumeral ligament (HAGL) lesion. *Arthroscopy* 2004;20:73-76 (suppl 2).
10. Meyer M, Gravelleau N, Hardy P, Landreau P. Anatomic risks of shoulder arthroscopy portals: Anatomic cadaveric study of 12 portals. *Arthroscopy* 2007;23:529-536.
11. Morgan CD, Burkhart SS, Palmeri M, Gillespie M. Type II SLAP lesions: Three subtypes and their relationships to superior instability and rotator cuff tears. *Arthroscopy* 1998;14:553-565.
12. Neviasser TJ. Arthroscopy of the shoulder. *Orthop Clin North Am* 1987;18:361-372.
13. Seroyer S, Tejwani SG, Bradley JP. Arthroscopic capsulolabral reconstruction of the type VIII superior labrum anterior posterior lesion: Mean 2-year follow-up on 13 shoulders. *Am J Sports Med* 2007;35:1477-1483.