

Contemporary Hip Capsular Management and Closure Using a Suture Passing Device



Edward C. Beck, M.D., M.P.H., Thomas Alter, M.S., Nabil Mehta, M.D.,
Jourdan M. Cancienne, M.D., Sara Sarmast, P.A., Joseph N. Liu, M.D., and
Shane J. Nho, M.D., M.S.

Abstract: Before comprehensive correction of femoroacetabular impingement syndrome, capsular management must be thoughtfully considered to ensure both adequate visualization for bony resection and prevention of iatrogenic micro-instability. A number of biomechanical and clinical studies have shown the importance of performing comprehensive capsular closure to restore native hip biomechanical kinematics. The purpose of this Technical Note is to describe the technique of using a suture passing device for capsular plication by a fellowship-trained hip arthroscopist at a large-volume academic center.

Perioperative capsular management during hip arthroscopy is critical to maintaining hip stability. A number of clinical and biomechanical studies have shown that not closing the capsule after capsulotomy can result in microinstability, iatrogenic macroscopic instability, and inferior postsurgical patient-reported outcomes.¹⁻⁵ Furthermore, others have shown that complete capsular repair leads to restoration of hip biomechanical properties back to the native intact hip, in addition to superior clinical outcomes.⁶⁻⁹

As evidence on the benefit of capsular closure continues to grow, surgeons have cautioned against leaving the capsule unrepaired after hip arthroscopy with capsulotomy.² However, despite mounting evidence on the importance of capsular management, many surgeons continue to leave the capsule unrepaired at the conclusion of the case. This may be reflective of the high technical demands of this portion of the procedure, which requires a thorough understanding of the capsular anatomy and arthroscopic techniques. For this reason, we present this Technical Note detailing the senior author's (S.J.N.) routine capsular plication technique using a suture passing device performed by a fellowship-trained hip arthroscopist at a large-volume academic center.

From the Section of Young Adult Hip Surgery, Division of Sports Medicine, Department of Orthopedic Surgery, Rush University Medical Center (E.C.B., T.A., N.M., J.M.C., S.S., S.J.N.), Chicago, Illinois, U.S.A.; and the Department of Orthopedic Surgery, Loma Linda University Medical Center (J.N.L.), Loma Linda, California, U.S.A.

The authors report the following potential conflicts of interest or sources of funding: S.J.N. reports nonfinancial support from Allosource, Arthrex, Athletico, DJ Orthopaedics, Linvatec, Miomed, Smith & Nephew, Stryker; other from American Journal of Orthopedics, American Orthopaedic Society for Sports Medicine, Arthroscopy Association of North America; personal fees from Ossur; personal fees and nonfinancial support from Springer. Full ICMJE author disclosure forms are available for this article online, as supplementary material.

Received February 17, 2019; accepted May 3, 2019.

Address correspondence to Shane J. Nho, M.D., M.S., Department of Orthopaedics, Rush University Medical Center, 1611 West Harrison St, Suite 300, Chicago, IL 60612, U.S.A. E-mail: shane.nho@rushortho.com or nho.research@rushortho.com

© 2019 by the Arthroscopy Association of North America. Published by Elsevier. This is an open access article under the CC BY-NC-ND license (<http://creativecommons.org/licenses/by-nc-nd/4.0/>).

2212-6287/19198

<https://doi.org/10.1016/j.eats.2019.05.003>

Surgical Techniques

Operative Indications

Capsulotomies have become a routine procedure in hip arthroscopy that provide improved intraoperative visualization of pathology in both the central and peripheral compartments of the hip joint. The risk of postoperative complications and inferior function because of improper capsular management has led to a growing majority of hip arthroscopists incorporating capsular closure after hip arthroscopy, particularly capsular plication in patients with a patulous capsule.^{8,10} Although continued debate exists as to the superiority of capsular closure over plication, our current practice uses capsular plication for all patients undergoing hip arthroscopy for femoroacetabular impingement, with the exception of those patients

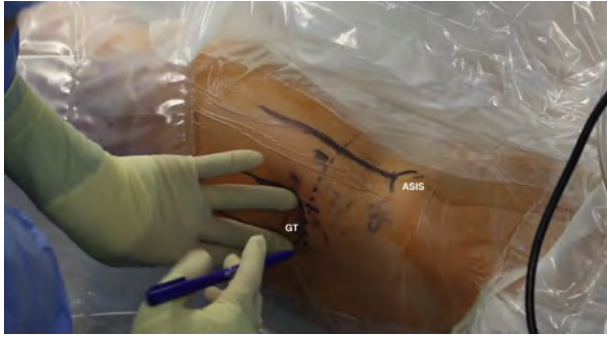

Fig 1. Supine position; right hip. Skin marking made to identify landmarks before incision. The anterior superior iliac spine is marked, and a vertical line is extended down the thigh toward the center of the patella, followed by outlining of the greater trochanter. GT, greater trochanter; ASIS, anterior superior iliac spine.

with capsular defects or insufficiency requiring reconstruction.

Patient Positioning

The patient is placed supine on a traction table, and general anesthesia is induced for complete muscle relaxation. The patient is then positioned on the table with a well-padded perineal post and boots. The pelvis is slightly translated toward the contralateral, nonoperative hip, and gentle distraction is applied across the operative limb. The operative limb is then placed in 20° of abduction and 20° of flexion, and manual distraction is applied. Gentle oscillations are used as the limb is slowly extended and adducted to obtain distraction up to 10 mm. The optimal position for the hip during this procedure is neutral adduction, extension of the extremity parallel to the floor, and internal rotation of 45° for maximal femoral neck length.

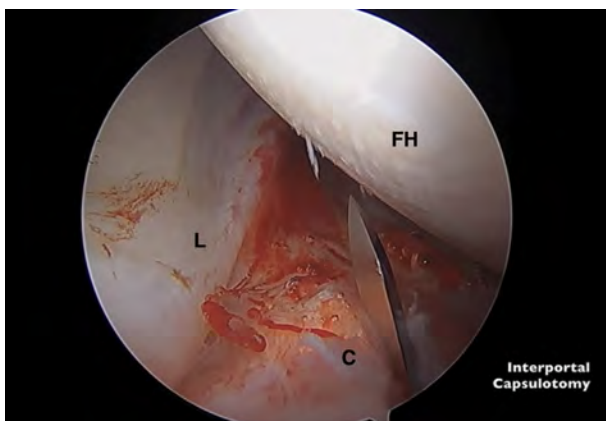


Fig 2. Supine position; right hip. Intra-articular arthroscopic image viewed from the anterior portal shows an arthroscopic scalpel used to make a transverse interportal capsulotomy, in a right hip, 8 to 10 mm from the labrum, extending from 12 to 2 o'clock, and with a length of 2 to 4 cm, depending on the extent of the intra-articular injury. C, capsule; FH, femoral head; L, labrum.

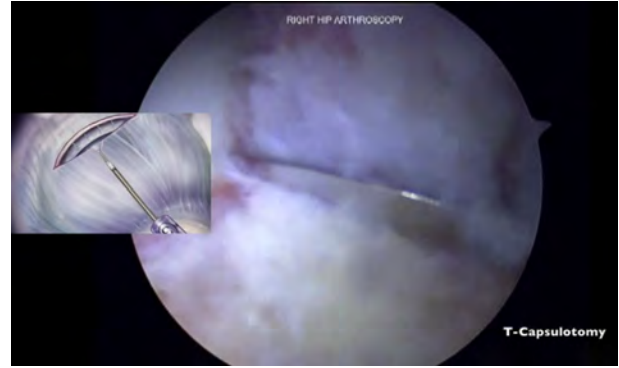


Fig 3. Supine position; right hip. Illustration (left) and intra-articular arthroscopic image (right) viewed from the anterior portal show conversion of an interportal to a T-capsulotomy to access the peripheral compartment in a right hip. Via the anterior portal, the arthroscope is placed into the peripheral compartment, and a T-capsulotomy is performed between the 12 and 2 o'clock positions to the intertrochanteric line.

Arthroscopic Technique and Interportal Capsulotomy

After sterile preparation and patient draping, the anterior superior iliac spine is marked, and a vertical line is extended down the thigh toward the center of the patella. The greater trochanter is then outlined (Fig 1). The anterolateral (AL) portal is first established under fluoroscopic visualization, penetrating the capsule at the 12 o'clock position. Standard cannulation allows for intra-articular visualization with a 70° arthroscope (Stryker Endoscopy, San Jose, CA). Under



Fig 4. Illustration shows the capsule being reflected by no. 2 high-molecular-weight polyethylene sutures in the medial and lateral leaflets of the iliofemoral ligament (IFL) to maximize visualization of the peripheral compartment. Both sutures are tensioned with a hemostat against the skin.

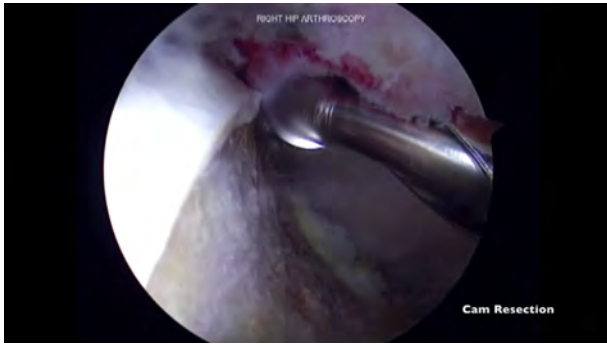


Fig 5. Supine position; right hip. Arthroscopic image viewed from the anterior portal shows correction of the femoral cam lesion in a right hip using a 5.5-mm bur.

direct visualization, the anterior portal is then created at the 2 o'clock position to minimize the size of the interportal capsulotomy. The arthroscope is switched to the anterior portal to view the position of the AL portal and ensure that it is adequate. A standard interportal capsulotomy is performed ~8 mm from the acetabulum using an arthroscopic scalpel (Samurai Blade; Stryker Sports Medicine) (Fig 2). The camera is then switched back to the AL portal, and the capsulotomy is completed around the area of chondrolabral injury (2 to 4 cm in length). A diagnostic arthroscopy is performed to evaluate the status of the labrum and any concomitant intra-articular pathology. Indicated procedures are then completed based on the intra-operative evaluation in the central compartment, including but not limited to acetabuloplasty, labral tear repair and or reconstruction, and microfracturing.

Vertical T-limb Capsulotomy and Capsular Plication

After completion of the procedures in the central compartment, traction is released, and the hip is typically flexed to 20° to access the peripheral compartment. Via the anterior portal, the arthroscope is placed into the peripheral compartment, and a T-capsulotomy is performed between the 12 and 2 o'clock positions to the intertrochanteric line (Fig 3). The suture passing

device (SlingShot Suture Manager; Stryker, Greenwood Village, CO) is used to reflect the capsule using no. 2 high-molecular-weight polyethylene sutures in the medial leaflet of the iliofemoral ligament (IFL) and another in the lateral leaflet of the IFL. The medial stitch is retrieved out of the distal anterolateral accessory (DALA) portal and tensioned with a hemostat against the skin (Fig 4). The lateral stitch is retrieved out of the AL portal and tensioned with a hemostat against the skin. With the capsule reflected, osteochondroplasty of the CAM deformity is performed with excellent visualization of the peripheral compartment. A combination of intra-operative fluoroscopy and dynamic hip examination confirms comprehensive correction of the CAM deformity from the lateral synovial folds to the medial synovial folds (Fig 5).

Once the arthroscopic procedure is complete, a complete capsular closure is performed to ensure normal biomechanical properties of the IFL. While viewing from the anterior portal, an 8.5 × 110-mm plastic cannula is placed in the DALA portal, and an 8.5 × 90-mm plastic cannula is placed in the AL portal. The previously placed suspension stitches are unclamped and used to repair the interportal capsulotomy. For the medial stitch, a looped retriever via the DALA portal is used to loosen the stitch and place it next to the medial aspect of the acetabular leaflet. The suture passing device is passed through the acetabular leaflet of the IFL, and filaments from the suture passing device are advanced to retrieve the suture (Fig 6). For the lateral stitch, a looped retriever via the AL portal is used to loosen the stitch and place it next to the lateral aspect of the acetabular leaflet. The suture passing device is passed through the acetabular leaflet of the IFL, and filaments from the suture passing device are advanced to retrieve the suture. To pass the middle stitch, a loaded suture passing device passes the suture from the middle of the acetabular leaflet. The unloaded suture passing device is passed through the apex of the T-capsulotomy to retrieve the suture. All 3 stitches are retrieved and left united until after the vertical aspect of

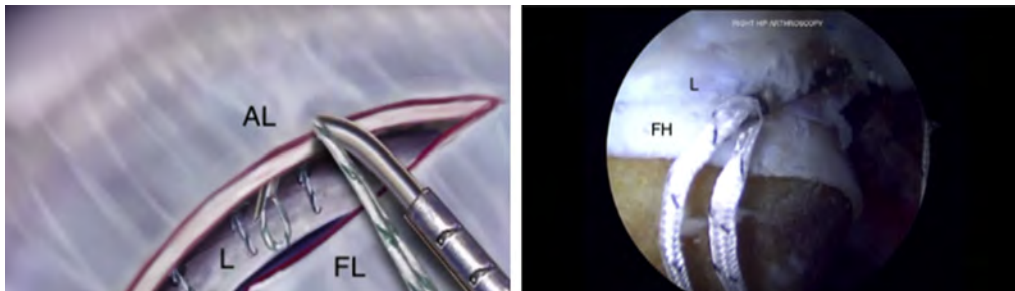


Fig 6. Illustration (left) and intra-articular arthroscopic image viewing from the anterior portal, supine position, right hip (right), show the shuttling suture device being placed through acetabular side of the interportal limb to begin closing the interportal limb in a right hip. The suture device is placed in the anterolateral portal in this image. AL, acetabular-sided leaflet; FH, femoral head; FL, femoral-sided leaflet; L, labrum.

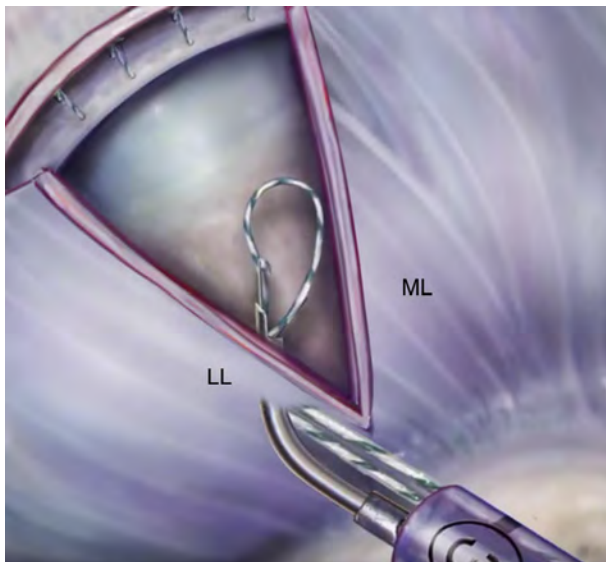


Fig 7. Illustration shows the shuttling suture device loaded with suture being inserted through the cannula in the DALA portal and passed through the medial limb of the vertical portion at the base of the T-capsulotomy. A 3-mm full-thickness bite is taken to ensure adequate purchase. DALA, distal anterolateral accessory; LL, lateral limb; ML, medial limb.

the T-capsulotomy is closed. Because it is more difficult to pass stitches in the interportal cut after the vertical aspect is closed, the authors recommend passing these stitches but not tying until after the vertical capsulotomy is closed.

The vertical T-limb of the T-capsulotomy is closed first, beginning at the base of the IFL using a suture passing device loaded with a no. 2 high-molecular-weight polyethylene suture. While viewing from the anterior portal, the suture passing device loaded with suture is inserted through the cannula in the DALA portal, and a full-thickness pass is made through the medial limb of the T-capsulotomy (Fig 7). The unloaded

suture passing device is then reinserted through the DALA portal, and a full-thickness pass is made through the lateral limb of the vertical portion at the base of the T-capsulotomy. If capsular plication is desired, wider bites from the capsulotomy can be taken to reduce capsular volume. The suture passing device then retrieves the suture passed through the medial leaflet (Fig 8). A standard arthroscopic knot is tied under direct visualization and cut. These steps are repeated, and 2 more sutures are passed in the vertical portion of the T-capsulotomy. Depending on the size of the incision and integrity of the capsule, the vertical T-limb is typically closed with 2 to 4 sutures. The interportal limb of the T-capsulotomy is repaired next. Of note, the process described here and shown in the video is for a right hip. For procedures involving the left hip, the shuttling suture device is inserted in through the AL portal.

Interportal Capsular Closure

The stitches that were previously passed for the interportal capsulotomy can be unclamped and tied sequentially. Beginning with the lateral stitch, a looped retriever can be used to pull the sutures through the cannula in the AL portal. If these stitches are difficult to identify in the extra-articular space, a knot pusher can be placed over these stitches to be more easily visualized. A standard arthroscopic knot is then tied under direct visualization. The hip can now be placed in neutral extension, and the remaining stitches can be tied to allow for neutral tension of the anterior capsule. The middle and medial stitches can be retrieved and tied sequentially (Fig 9). With the capsule completely repaired, the femoral head articular cartilage should no longer be visible.

Postoperative Rehabilitation

Rehabilitation is started on postoperative day 1 for all patients as previously described.⁸ Patients go through a

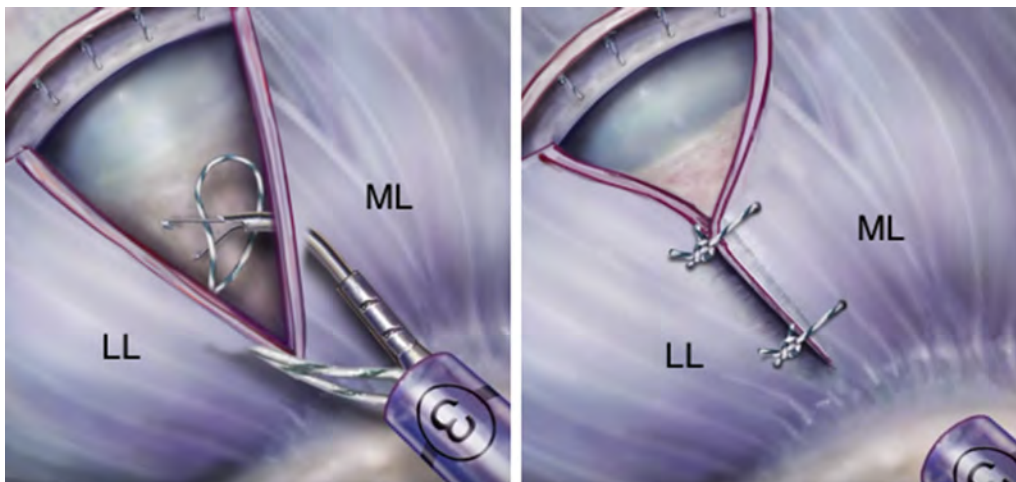


Fig 8. Illustration on the left shows the unloaded device being inserted through the DALA portal and a full-thickness 6-mm pass being made through the lateral leaflet. Illustration on the right shows the importance of taking a larger bite through the lateral leaflet to ensure proper capsular plication. DALA, distal anterolateral accessory; LL, lateral limb; ML, medial limb.

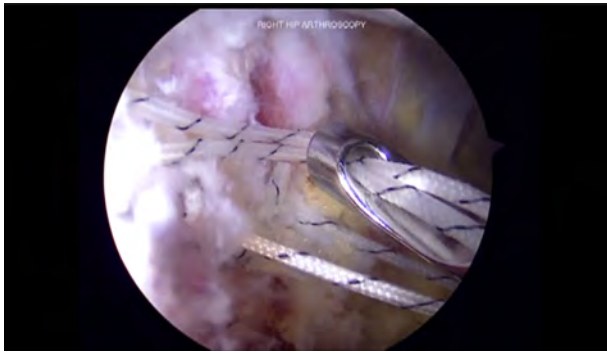

Fig 9. Supine position; right hip. Intra-articular arthroscopic image viewing from the anterior portal shows one of the stitches being tied using arthroscopic techniques in a right hip. The sutures in the interportal limb are tagged once tied, and then cut once the other 2 interportal capsulotomy sutures have been placed.

4-phase rehabilitation protocol that lasts an average of 16 to 18 weeks. Rehabilitation phase 1 prioritizes joint protection and soft tissue mobilization techniques. Our preference is to use a night splint and hip orthosis (Hip Rebound Brace, Ossur, Foothill Ranch, CA) for the first month after surgery to protect the capsular repair. Early circumduction is recommended but excessive extension and external rotation should be avoided for the first couple weeks. Phase 2 focuses on normal gait maintenance, full range of motion restoration, improvement of neuromuscular control, and maintenance of pelvic and core stability. Phase 3 incorporates single leg squats and strengthening, soft tissue and joint mobilization, and cardiovascular fitness. Phase 4 emphasizes return to preinjury level of sports participation. Patients are cleared to return to sports if they are able to participate in sports without pain, have full dynamic functional control, and pass all return-to-sports tests.

Discussion

This Technical Note describes a method of capsular closure and plication using a suture management device. We recognize that capsular management is technically challenging and therefore provided a visual guide for orthopaedic specialists less experienced in hip arthroscopy and capsular closure. The benefits of using the suture shuttling device for capsular closure are many. First, the suture is passed and retrieved easily

Table 1. Advantages and Disadvantages of Capsular Plication

Advantages	Disadvantages
Prevents iatrogenic dislocation or subluxation	Longer surgical time
Helps maintain the stability of the hip joint	Technically challenging
Prevents edge loading of repaired labrum	Risk of damaging articular surface
	Nonabsorbable sutures left in capsule

using the same device, requiring less surgical equipment in the surgical field. Second, the suture can be visibly passed from 1 leaflet to the other, ensuring adequate purchase for capsular closure via plication or approximation of the leaflets. Finally, slingshot suture management prevents iatrogenic chondral damage when passing the suture blindly from 1 leaflet to another as with other arthroscopic capsular closure devices.

Capsular management strategies must be considered before comprehensive correction of any intraarticular hip pathology that balances adequate visualization and the opportunity for complete closure. To prevent hip macro- and microinstability, it is critical to understand the structure and function of the iliofemoral ligament. Complete anatomic repair of the iliofemoral ligament restores the biomechanical characteristics of the capsule, including axial strain, translation, and rotation.^{5,7,11} More recent biomechanical studies have shown that proper capsular plication of T-capsulotomy leads to a quantifiable decrease in intra-articular volume.⁹ Clinically, complete capsular closure has shown improved patient-reported outcomes and increased survivorship compared with partial closure. Frank et al.⁸ reported superior sport-specific outcomes in the complete versus partial closure group. Furthermore, there was a 13% revision rate in the partial closure group, with none seen in their counterparts.

The advantages and disadvantages of our capsular plication technique are listed in Table 1. Plication of the capsulotomy after hip arthroscopy can help maintain the stability of the joint, preventing iatrogenic subluxation, dislocation, and microinstability.¹² The disadvantages include increased surgical time, potential to damage the acetabular surface, and increased technical demand. Furthermore, there is significant debate about capsular closure in cases of stiff hips and radiographic signs of arthritic changes.¹³ Nonetheless, the growing evidence of benefits for capsular closure in the majority of patient populations has led to improved methods and

Table 2. Pearls and Pitfalls of Capsular Closure

Pearls	Pitfalls
Tailor the degree of capsulotomy depending on whether the patient has generalized ligamentous laxity.	Avoid over-aggressive capsulotomy, which can prevent complete closure or cause unnecessary tension after closing, resulting in postoperative stiffness.
Capsular closure should begin at the distal base of the IFL and location of T-capsulotomy, progressing proximally toward the interportal capsulotomy.	Avoid hip extension or external rotation during postoperative rehabilitation, as these can stress the repaired capsule.

IFL, iliofemoral ligament.

dissemination of techniques such as this for assisting current and future orthopaedic surgeons in improving their hip arthroscopy outcomes. Pearls and pitfalls of capsular repair are described in [Table 2](#).

In conclusion, capsular management and capsular plication techniques described in this article provide a step-by-step process to ensure that both emerging and established hip arthroscopists are able to perform the challenging procedure. Growing evidence has shown that capsular closure leads to decreased complications and restores the biomechanical properties of the hip to its native intact state.

References

1. Duplantier NL, McCulloch PC, Nho SJ, Mather RC 3rd, Lewis BD, Harris JD. Hip dislocation or subluxation after hip arthroscopy: A systematic review. *Arthroscopy* 2016;32:1428-1434.
2. Wylie JD, Beckmann JT, Maak TG, Aoki SK. Arthroscopic capsular repair for symptomatic hip instability after previous hip arthroscopic surgery. *Am J Sports Med* 2016;44:39-45.
3. Yeung M, Memon M, Simunovic N, Belzile E, Philippon MJ, Ayeni OR. Gross instability after hip arthroscopy: An analysis of case reports evaluating surgical and patient factors. *Arthroscopy* 2016;32:1196-1204. e1191.
4. Abrams GD, Hart MA, Takami K, et al. Biomechanical evaluation of capsulotomy, capsulectomy, and capsular repair on hip rotation. *Arthroscopy* 2015;31:1511-1517.
5. van Arkel RJ, Amis AA, Cobb JP, Jeffers JR. The capsular ligaments provide more hip rotational restraint than the acetabular labrum and the ligamentum teres: An experimental study. *Bone Joint J* 2015;97-B:484-491.
6. Wuerz TH, Song SH, Grzybowski JS, et al. Capsulotomy size affects hip joint kinematic stability. *Arthroscopy* 2016;32:1571-1580.
7. Myers CA, Register BC, Lertwanich P, et al. Role of the acetabular labrum and the iliofemoral ligament in hip stability: An in vitro biplane fluoroscopy study. *Am J Sports Med* 2011;39:85S-91S (suppl).
8. Frank RM, Lee S, Bush-Joseph CA, Kelly BT, Salata MJ, Nho SJ. Improved outcomes after hip arthroscopic surgery in patients undergoing T-capsulotomy with complete repair versus partial repair for femoroacetabular impingement: A comparative matched-pair analysis. *Am J Sports Med* 2014;42:2634-2642.
9. Waterman BR, Chen A, Neal WH, et al. Intra-articular volume reduction with arthroscopic plication for capsular laxity of the hip: A cadaveric comparison of two surgical techniques. *Arthroscopy* 2019;35:471-477.
10. Saltzman BM, Kuhns BD, Basques B, et al. The influence of body mass index on outcomes after hip arthroscopic surgery with capsular plication for the treatment of femoroacetabular impingement. *Am J Sports Med* 2017;45:2303-2311.
11. Khair MM, Grzybowski JS, Kuhns BD, Wuerz TH, Shewman E, Nho SJ. The effect of capsulotomy and capsular repair on hip distraction: A cadaveric investigation. *Arthroscopy* 2017;33:559-565.
12. Harris JD, Slikker W 3rd, Gupta AK, McCormick FM, Nho SJ. Routine complete capsular closure during hip arthroscopy. *Arthrosc Tech* 2013;2:e89-e94.
13. Abrams GD. Editorial Commentary: The importance of capsular closure in hip arthroscopy: Is there a limit to the benefit? *Arthroscopy* 2018;34:864-865.