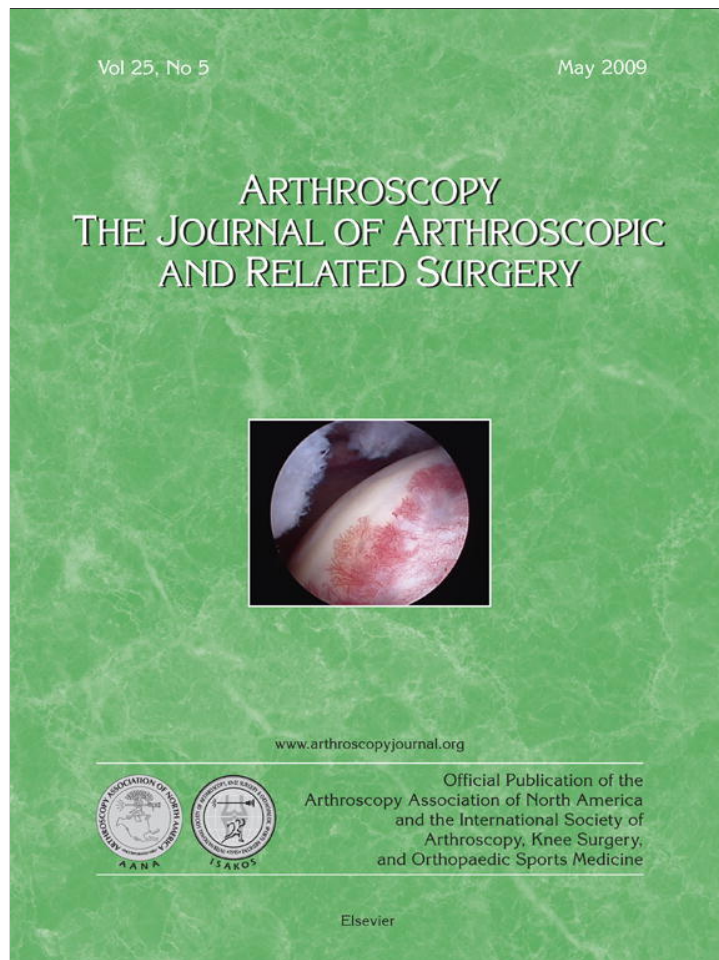

This article appeared in a journal published by Elsevier. The attached copy is furnished to the author for internal non-commercial research and education use, including for instruction at the authors institution and sharing with colleagues.

Other uses, including reproduction and distribution, or selling or licensing copies, or posting to personal, institutional or third party websites are prohibited.

In most cases authors are permitted to post their version of the article (e.g. in Word or Tex form) to their personal website or institutional repository. Authors requiring further information regarding Elsevier's archiving and manuscript policies are encouraged to visit:

<http://www.elsevier.com/copyright>

Technical Note With Video Illustration

Anatomic Reduction and Next-Generation Fixation Constructs for Arthroscopic Repair of Crescent, L-Shaped, and U-Shaped Rotator Cuff Tears

Shane J. Nho, M.D., M.S., Neil Ghodadra, M.D., Matthew T. Provencher, M.D., Stefanie Reiff, B.A., and Anthony A. Romeo, M.D.

Abstract: Emerging techniques and instrumentation have allowed orthopaedic surgeons to achieve rotator cuff repair through an all-arthroscopic technique. The most critical steps in rotator cuff repair consist of proper identification of the cuff tear pattern and anatomic restoration of the torn tendon footprint. With anatomic reduction of the rotator cuff tendons, a sound fixation construct can help restore rotator cuff contact pressure and kinematics, allowing for decreased repair tension and optimal healing potential. We provide surgical methods to recognize tear patterns and present a repair construct that will restore the anatomic footprint of the torn rotator cuff tendon. The key, initial maneuver to restore the anatomic footprint of the cuff includes placement of a suture anchor at the anterolateral corner for L-shaped tears and at the posterolateral corner for reverse L-shaped and U-shaped tears. After insertion of the medial-row anchors, the tendon stitches should be planned by use of a grasper to hold the tendon in a reduced position and guide location of the stitch. The lateral row with suture bridge can be visualized, and the final repair construct should produce an anatomic restoration of the rotator cuff footprint. **Key Words:** Shoulder—Rotator cuff—Crescent tear—U-shaped tear—L-shaped tear.

As rotator cuff repair transitions from the traditional open technique to the emerging arthroscopic technique, it is of the utmost importance to recognize and distinguish the rotator cuff tear patterns

for proper fixation and healing.¹⁻⁴ Repair of rotator cuff tears can be likened to fracture fixation—an anatomic reduction will provide the best restoration of kinematics, with the best potential for healing, because the construct will be under minimal tension. It is imperative to distinguish multiple but common rotator cuff tear patterns to obtain the most exact “reduction” of the cuff tear that is possible.

Burkhart and Lo² classified rotator cuff tears into 4 major categories: crescent, U-shaped, L-shaped, and massive. The crescent tear has medial to lateral mobility that can be repaired directly to bone with minimal tension (Fig 1). The U-shaped tear extends farther than the crescent with its apex more medial to the glenoid rim (Fig 2). Burkhart and Lo note the importance of recognizing this tear and completing side-to-side sutures to reduce tension and achieve marginal convergence; without this technique, the tension of the

From the Section of Shoulder & Elbow Surgery, Division of Sports Medicine, Department of Orthopedic Surgery, Rush University Medical Center, Rush Medical College of Rush University (S.J.N., N.G., S.R., A.A.R.), Chicago, Illinois, and Division of Shoulder, Knee and Sports Surgery, Naval Medical Center San Diego (M.T.P.), San Diego, California, U.S.A.

The authors report no conflict of interest.

Address correspondence and reprint requests to Shane J. Nho, M.D., M.S., Rush University Medical Center, 1725 W Harrison St, Suite 1063, Chicago, IL 60612, U.S.A. E-mail: snho@hotmail.com
© 2009 by the Arthroscopy Association of North America
0749-8063/09/2505-0096\$36.00/0
doi:10.1016/j.arthro.2009.01.024

Note: To access the supplementary videos accompanying this report, visit the May issue of *Arthroscopy* at www.arthroscopyjournal.org.

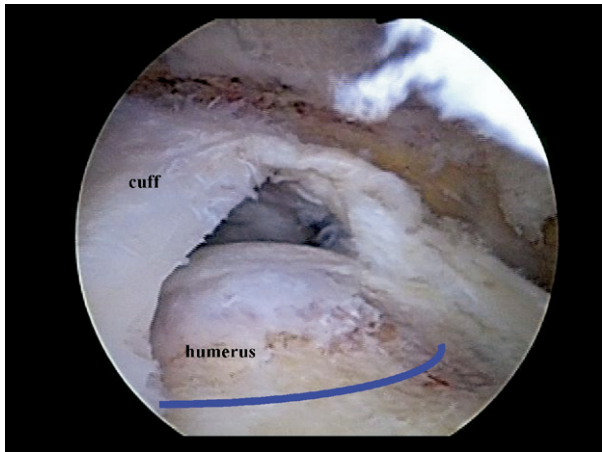


FIGURE 1. Arthroscopic view of left shoulder from lateral portal showing crescent-shaped rotator cuff tear. The blue line shows the anatomic footprint of the supraspinatus tendon.

repair is too great and potentially results in a high incidence of failure. The L-shaped tear is similar to the U-shaped tear; however, one side of the tear is more mobile than the other and thus easier to bring to bone (Fig 3). These first 3 patterns represent over 90% of rotator cuff tears, with the crescent and U-shaped tears being the most common.^{1,2} The fourth classification by Burkhart and Lo is the massive, contracted immobile tear. This tear lacks medial to lateral mobility and can be longitudinal or crescent.

With the development of new fixation devices and surgical techniques, fixation constructs are constantly evolving to provide a stronger and more reliable bio-

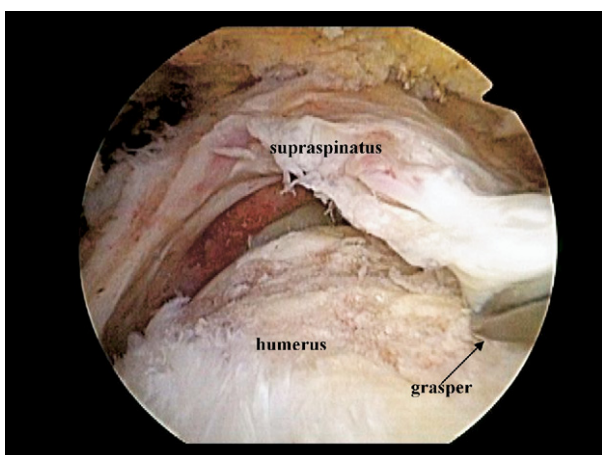


FIGURE 2. Arthroscopic view of left shoulder from lateral portal showing U-shaped rotator cuff tear with involvement of supraspinatus tendon and anterior aspect of infraspinatus tendon.

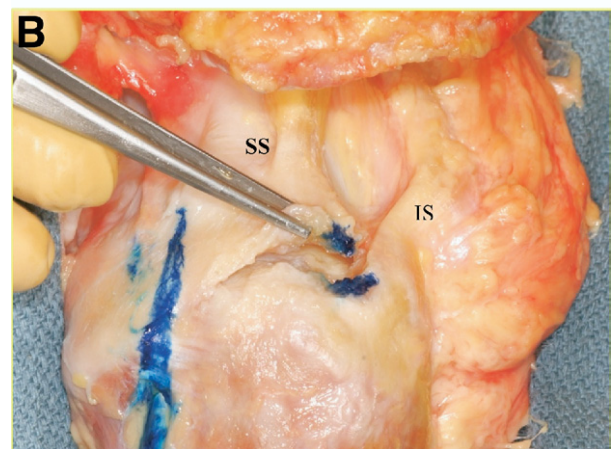
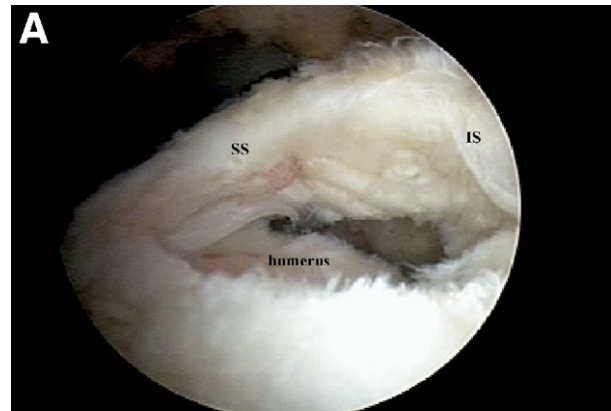


FIGURE 3. (A) Arthroscopic view of left shoulder from lateral portal showing reverse L-shaped rotator cuff tear with a very short split from lateral to medial between supraspinatus (SS) and infraspinatus (IS) tendons. (B) Superior view of cadaveric reverse L-shaped rotator cuff tear. The grasper is shown pulling the posterolateral corner of the supraspinatus back to its anatomic footprint.

mechanical construct. Despite the innovations in rotator cuff repair, it is of the utmost importance to recognize the tear pattern to correctly restore the tendon to the bone, thus maximizing the contact with the footprint of the rotator cuff and increasing the amount of healing.^{2,3} The purpose of this article is to provide surgical methods to recognize tear patterns and devise a repair construct that will restore the anatomic footprint of the torn rotator cuff tendon.

SURGICAL TECHNIQUE

Patient Positioning

Although both the beach-chair and lateral decubitus positions have been described for rotator cuff repair

surgery, we prefer to place the patient in the beach-chair position to facilitate visual orientation of cuff tear “reduction.” After standard preparation and draping, the acromion, distal clavicle, and coracoid process are outlined with a marking pen. A posterior portal is created approximately 1 to 2 cm inferior and in line with the posterolateral acromion. The 30° arthroscope is inserted, and diagnostic glenohumeral arthroscopy is performed. An initial anterosuperior portal is created high in the rotator interval with an outside-in technique after localization with an 18-gauge spinal needle, directly adjacent to the long head of the biceps tendon. The articular side of the rotator cuff is then visualized, and the surgeon can estimate the coronal and sagittal plane dimensions of the articular portion of the rotator cuff tear. In addition, important findings of partial tears may be noted including the amount of footprint involvement. It should be noted that the supraspinatus tendon attaches directly adjacent to the articular margin of the humeral head (Fig 1). A medial to lateral loss of cuff attachment of approximately 6 to 8 mm represents a 50% partial-thickness rotator cuff tear.⁵ The rotator cuff tear may be marked with a spinal needle and No. 1 monofilament suture inserted from the lateral edge of the acromion. This suture may be easily identified in the subacromial space to locate the rotator cuff tear.

The arthroscopic equipment is then moved into the subacromial space. A lateral portal is established under direct visualization. Soft tissue is removed from the undersurface of the acromion, and the coracoacromial ligament is released subperiosteally and debrided back to a smooth and stable edge. If desired, an acromioplasty is performed at this point.

Tear Pattern Recognition

From a direct lateral portal at the 50-yard line of the acromion, the rotator cuff tear pattern is best appreciated. With the arthroscope in this lateral portal, an anterolateral portal is made directly off the most anterior and lateral edge of the acromion and a 7-mm cannula is inserted. This will serve as the working portal with the arthroscope maintained in the lateral portal to accomplish the cuff repair.

The most critical portion of the case is to identify the tear pattern, because this will dictate the optimal fixation construct and ensure proper reduction of the rotator cuff tear. The rotator cuff edges are gently debrided, and the overall medial-lateral and anterior-posterior mobility of the tear is assessed. By use of an arthroscopic grasper from the posterior portal, the torn

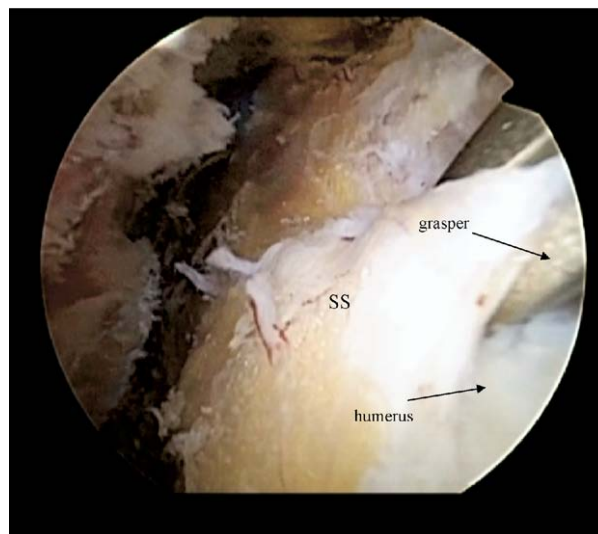


FIGURE 4. Arthroscopic view of right shoulder from posterior portal showing anatomic reapproximation of supraspinatus (SS) to its anatomic footprint with a grasper.

tendon edges are grasped and pulled laterally to the site of origin to approximate the appearance with fixation (Fig 4). The crescent tear generally can be seen without much manipulation of the tendon and can be easily reduced to the supraspinatus footprint. The L-shaped and reverse L-shaped tears become more obvious while the tendon is being grasped. With L-shaped tears, the anterolateral corner of the torn tendon is grasped and pulled over the anterolateral aspect of the greater tuberosity. Reverse L-shaped tears require grasping of the posterolateral corner of the torn tendon and reapproximating it to the posterolateral aspect of the greater tuberosity adjacent to the infraspinatus footprint (Fig 5) (Video 1, online only, available at www.arthroscopyjournal.org). The U-shaped tear is a larger tear that generally involves the supraspinatus and infraspinatus tendons. The scapular spine is a good landmark to estimate the posterior and anterior boundaries of the supraspinatus and infraspinatus tendons, respectively. In most cases the grasper can reduce the posterolateral corner of the supraspinatus and anterolateral corner of the infraspinatus to their respective footprints.

The reduction of an L-shaped tear and reverse L-shaped tear is important to obtain the correct orientation of the apices. The corner of L-shaped tears should easily reduce and approximate the lateral cable of the rotator cuff, and the bottom tip of the “L” should also fit into place either at the anterior edge of the supraspinatus or at the posterior edge of the su-

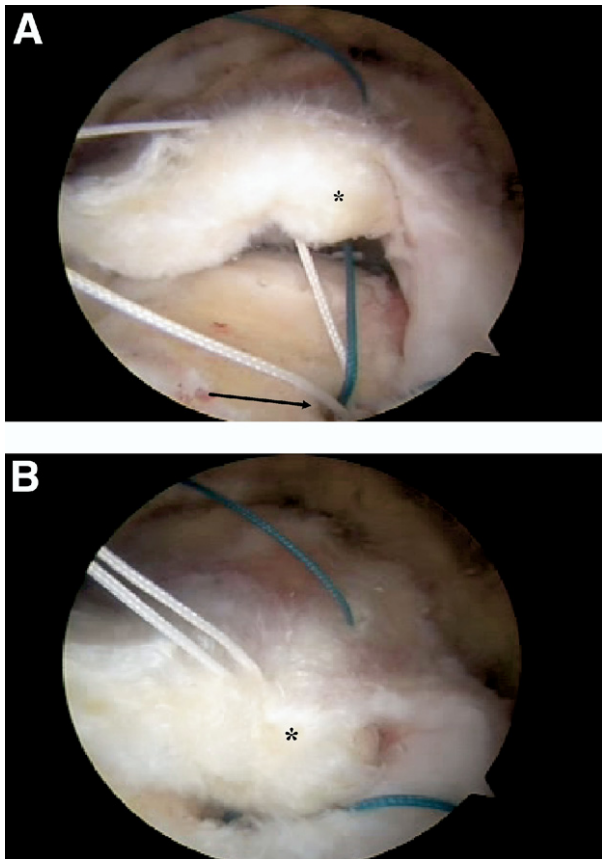


FIGURE 5. Arthroscopic view of left shoulder from lateral portal showing a reverse L-shaped cuff tear. (A) Placement of suture anchor at posterolateral anatomic footprint of supraspinatus. The asterisk denotes the posterolateral portion of the supraspinatus, and the arrow points to the site of anatomic reduction of the posterolateral corner of the supraspinatus. (B) Reapproximation of posterolateral corner of supraspinatus to anatomic footprint. The asterisk denotes the posterolateral portion of the supraspinatus.

praspinatus, depending on how the tear propagated. Usually, the tear propagates up the rotator interval; thus the tip of the “L” in a right shoulder is anterior and would be the tip of the “L” in a reverse L tear for a left shoulder (Fig 6). A temporary loose reduction stitch may be placed arthroscopically to anatomically reduce an L-shaped rotator cuff tear. Visualization from the lateral portal during this entire procedure is critical to obtain an anatomic reduction.

Fixation Technique

The points of fixation can be planned while the torn tendon is held in its reduced position, and the surgeon should bear in mind the type of suture anchor, row configuration, and use of suture bridge. In all tears that have a full-thickness component, we

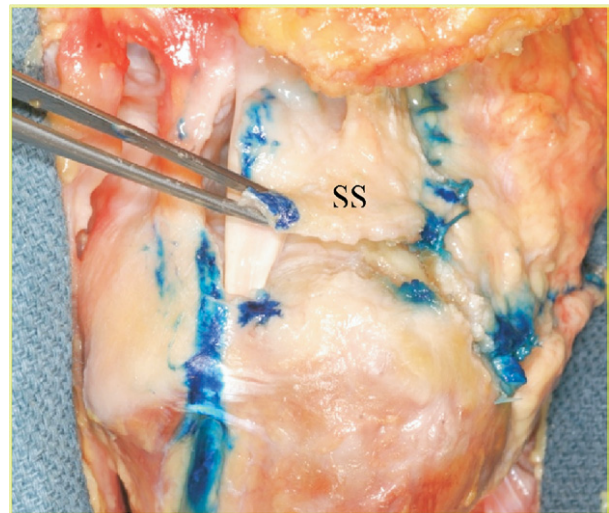


FIGURE 6. Superior view of cadaveric left shoulder with L-shaped rotator cuff tear. The grasper is shown pulling the anterolateral corner of the supraspinatus (SS) back to its anatomic footprint.

have used double-row fixation with a transosseous-equivalent technique⁶ (Fig 7) (Video 2, online only, available at www.arthroscopyjournal.org).

A spinal needle is used to localize anchor placement, and a 6.0- to 7.0-mm threaded cannula is used through an accessory portal for suture passage and knot tying. The medial row is created with 2 anchors (4.75-mm SwiveLock; Arthrex, Naples, FL) loaded with nonabsorbable suture tape (FiberTape; Arthrex) and placed at the juxta-articular margin (Fig 8). While an assistant is holding the arthroscope, the surgeon is able to hold the tendon in its reduced position and use

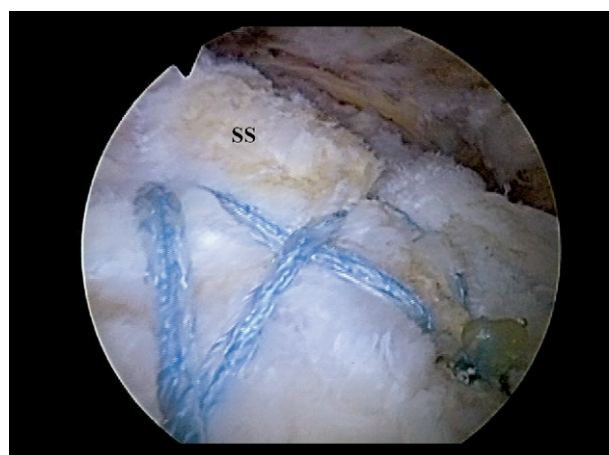


FIGURE 7. Arthroscopic view of right shoulder from posterior portal, with double-row suture anchor with suture bridge used to restore anatomic footprint of supraspinatus (SS).

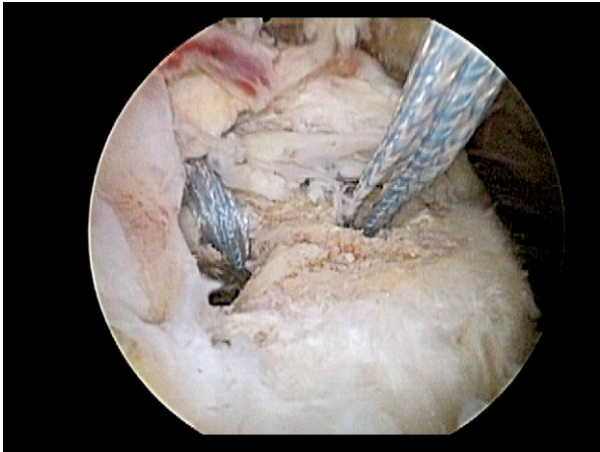

FIGURE 8. Arthroscopic view of right shoulder from lateral portal showing placement of medial-row suture anchors.

either a penetrator or curved suture lasso to provide the first point of fixation just lateral to the musculo-tendinous junction of the tendons. The suture tape is passed through the tendon and delivered out the anterior portal for the anterior anchor and the posterior portal for the posterior anchor. In cases of a reverse L-shaped tear or an L-shaped tear, a single 4.5-mm fully threaded anchor (Bio-Corkscrew; Arthrex) can be placed at the corner of the tear, and then the sutures can be individually passed through the corner of the rotator cuff tendon to bring this into its anatomic position (**Fig 5B**). This is a critical point to determine correct placement of the tendon sutures, and it allows

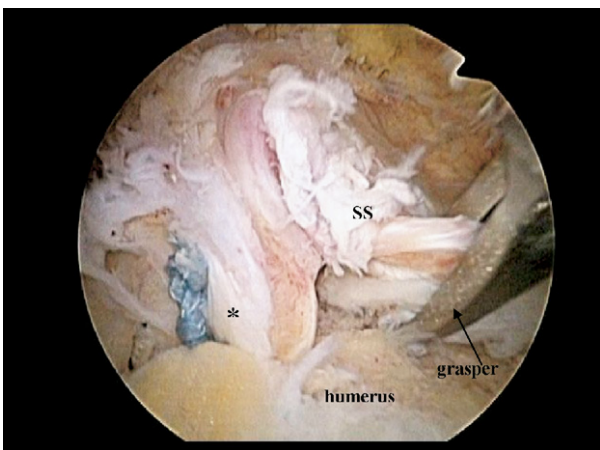


FIGURE 9. Arthroscopic view of right shoulder from lateral portal showing conversion of a U-shaped tear to a reverse L-shaped cuff tear after suture anchor fixation of anterolateral aspect of infraspinatus. The asterisk denotes fixation of the anterolateral aspect of the infraspinatus. (SS, supraspinatus.)

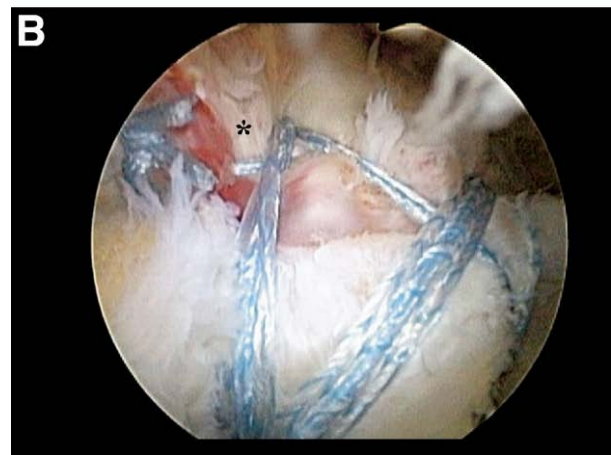
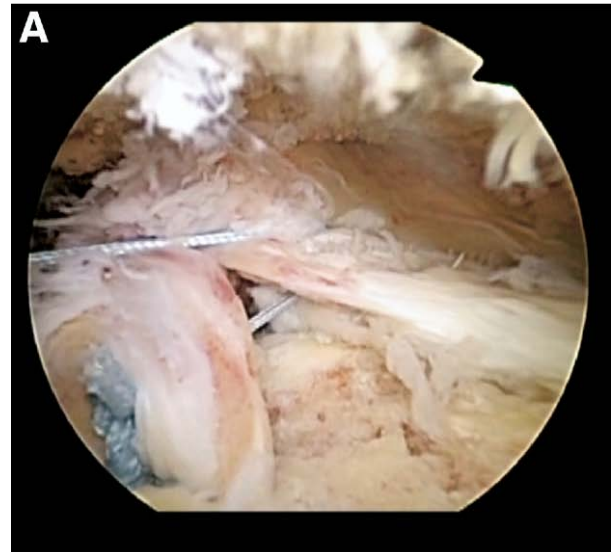


FIGURE 10. Arthroscopic view of right shoulder from lateral portal after conversion of a U-shaped cuff tear to a reverse L-shaped tear. (A) Side-to-side stitch from infraspinatus tendon to supraspinatus tendon with infraspinatus in a reduced position. (B) Final repair construct. The asterisk shows the side-to-side stitch also acting as a rip-stop tendon stitch.

for anatomic reduction of the supraspinatus tendon. In the case of a U-shaped tear, the anterolateral corner of the infraspinatus can be fixed by use of a single 4.5-mm fully threaded anchor, which may convert the U-shaped tear to a reverse L-shaped tear (**Fig 9**). We also advocate inserting a side-to-side stitch from the infraspinatus tendon to the supraspinatus tendon with the supraspinatus in a reduced position; in addition, the stitch acts as a rip-stop stitch in a double-row fixation construct (**Fig 10**). For massive, contracted, immobile tears, we recommend repairing the subscapularis to its anatomic position on

the lesser tuberosity and the infraspinatus to its anatomic position at the leading edge at the upper border of the bare area of the humerus. Once the subscapularis and infraspinatus are stabilized, every attempt is made to perform a transosseous-suture bridge configuration for fixation of the supraspinatus without margin convergence. Crescent or L-shaped tears extend into the adjacent tendons, ultimately resulting in a U-shaped tear. We believe that initial restoration of the subscapularis and infraspinatus back to their anatomic position provides the surgeon a more facile anatomic rotator cuff repair than beginning the repair with margin convergence.

Once the tendon is reduced to its anatomic position, one strand of suture tape is retrieved from each of the two tendon fixation points and pulled out of the accessory portal. The surgeon can tension the suture tape and plan for the lateral-row anchor placement to produce an anatomic restoration. Next, a radiofrequency energy device can be used to mark placement of the lateral-row anchors by removing the overlying soft tissue on the humeral head. Two additional anchors (SwiveLock; Arthrex) are then placed in an appropriate fashion on the lateral aspect of the humerus so that a crossing pattern to the suture tape over the top of the rotator cuff tendon is achieved (Fig 7) (Video 2, online only, available at www.arthroscopyjournal.org). This configuration provides a secure and stable repair of the rotator cuff tendon into an anatomic position by use of a knotless fixation technique. Soft tissue and bony debris are then irrigated out thoroughly, completing the arthroscopic portion of the surgical procedure.

DISCUSSION

As arthroscopic rotator cuff repair continues to evolve, different techniques for restoring the footprint of the rotator cuff and, thus, achieving an anatomic rotator cuff repair have been suggested.⁷ The arthroscope allows for excellent visualization of the type and configuration of cuff tear, and improved techniques and instrumentation now allow for anatomic reduction of the repair to be achieved. Just as in fracture fixation, an anatomic repair of the rotator cuff is instrumental in achieving maximal biomechanical restoration of cuff anatomy. With anatomic reduction of the rotator cuff tendons, a sound fixation construct can help restore rotator cuff contact pressure and kinematics, allowing for decreased repair tension and optimal healing potential.

Studies show that the single-row technique, in which suture anchors are placed linearly over the lateral edge of

the rotator cuff footprint, achieves only point fixation and fails to restore the contact area of the anatomic footprint.⁷⁻¹¹ To increase the restored area of the footprint, a double-row technique, which adds a medial row of suture anchors at the articular cartilage margin to the row placed along the lateral edge of the rotator cuff footprint, has been introduced.^{9,12-15} The double-row technique provides up to 74% more footprint coverage according to Nelson et al.¹⁶ and is reported by Charouset et al.⁸ to increase anatomic healing by 21% compared with the single-row technique. To decrease tension when repairing the rotator cuff, especially in U-shaped tears, Burkhart and Lo² suggest medial to lateral side suturing, resulting in marginal convergence and repair to the bone bed with minimal tension.

Many alterations of the double-row repair exist by varying the type of sutures used. For instance, Lo and Burkhart⁷ use a medial-row mattress suture and a lateral-row simple suture, whereas Nelson et al.¹⁶ report that Millett¹⁷ uses a mattress suture double anchor. Nelson et al.¹⁶ detail a modified Mason-Allen stitch with the suture anchor. Franceschi et al.¹⁸ apply a combined double pulley-suture bridge technique, coined the Roman bridge, to combine the secure fixation aspect of the pulley with the improved pressure and strength over the footprint from the suture. An additional double-row technique involves the combination of transosseous tunnels and suture anchors, which mimics the technique used during an open rotator cuff repair.¹⁹⁻²² This technique also increases contact area with the footprint when compared with the single-row technique.¹⁸ Cole et al.⁹ report an almost 50% increase in footprint contact area with this transosseous technique as compared with the double-row repair, and Nelson et al.¹⁶ report that Tuoheti et al.²³ describe a 42% increase in contact area when using the double-row technique as opposed to the transosseous-equivalent technique.

Arthroscopic rotator cuff repair continues to evolve with the introduction of new fixation devices and surgical techniques. One of the most critical aspects of arthroscopic rotator cuff repair is the recognition and anatomic reduction of tear patterns. Burkhart¹ and Burkhart and Lo² report that over 90% of rotator cuff tears have a crescent, L-shaped, or U-shaped pattern, and the surgeon should identify the proper tear pattern and develop an appropriate fixation construct. Knowledge of the tear pattern will allow the strategic placement of tendon stitches and suture anchors to counteract the retraction forces. We believe that placement of a suture anchor at the anterolateral corner for L-shaped tears and at the posterolateral corner for re-

verse L-shaped and U-shaped tears is the initial step that facilitates anatomic restoration of the footprint. Thereafter the medial row can be inserted, and the tendon stitches should be planned by use of a grasper to hold the tendon in a reduced position and guide location of the stitch. The lateral row with suture bridge can be visualized, and the final repair construct should produce an anatomic restoration of the rotator cuff footprint.

REFERENCES

- Burkhart SS. Arthroscopic treatment of massive rotator cuff tears. *Clin Orthop Relat Res* 2001;107-118.
- Burkhart SS, Lo IK. Arthroscopic rotator cuff repair. *J Am Acad Orthop Surg* 2006;14:333-346.
- Sallay PI, Hunker PJ, Lim JK. Frequency of various tear patterns in full-thickness tears of the rotator cuff. *Arthroscopy* 2007;23:1052-1059.
- Yadav H, Nho S, Romeo A, Macgillivray JD. Rotator cuff tears: Pathology and repair. *Knee Surg Sports Traumatol Arthrosc* 2009;17:409-421.
- Lo IK, Burkhart SS. Transtendon arthroscopic repair of partial-thickness, articular surface tears of the rotator cuff. *Arthroscopy* 2004;20:214-220.
- Park MC, ElAttrache NS, Ahmad CS, Tibone JE. "Transosseous-equivalent" rotator cuff repair technique. *Arthroscopy* 2006;22:1360.e1-1360.e5. Available online at www.arthroscopyjournal.org.
- Lo IK, Burkhart SS. Double-row arthroscopic rotator cuff repair: Re-establishing the footprint of the rotator cuff. *Arthroscopy* 2003;19:1035-1042.
- Charousset C, Grimberg J, Duranthon LD, Bellaiche L, Petrover D. Can a double-row anchorage technique improve tendon healing in arthroscopic rotator cuff repair? A prospective, nonrandomized, comparative study of double-row and single-row anchorage techniques with computed tomographic arthrography tendon healing assessment. *Am J Sports Med* 2007;35:1247-1253.
- Cole BJ, ElAttrache NS, Anbari A. Arthroscopic rotator cuff repairs: An anatomic and biomechanical rationale for different suture-anchor repair configurations. *Arthroscopy* 2007;23:662-669.
- Lafosse L, Brozka R, Toussaint B, Gobeze R. The outcome and structural integrity of arthroscopic rotator cuff repair with use of the double-row suture anchor technique. *J Bone Joint Surg Am* 2007;89:1533-1541.
- Ko SH, Lee CC, Friedman D, Park KB, Warner JJ. Arthroscopic single-row supraspinatus tendon repair with a modified mattress locking stitch: A prospective, randomized controlled comparison with a simple stitch. *Arthroscopy* 2008;24:1005-1012.
- Baums MH, Buchhorn GH, Spahn G, Poppendieck B, Schultz W, Klinger HM. Biomechanical characteristics of single-row repair in comparison to double-row repair with consideration of the suture configuration and suture material. *Knee Surg Sports Traumatol Arthrosc* 2008;16:1052-1060.
- Huijsmans PE, Pritchard MP, Berghs BM, van Rooyen KS, Wallace AL, de Beer JF. Arthroscopic rotator cuff repair with double-row fixation. *J Bone Joint Surg Am* 2007;89:1248-1257.
- Sugaya H, Maeda K, Matsuki K, Moriishi J. Repair integrity and functional outcome after arthroscopic double-row rotator cuff repair. A prospective outcome study. *J Bone Joint Surg Am* 2007;89:953-960.
- Anderson K, Boothby M, Aschenbrener D, van Holsbeeck M. Outcome and structural integrity after arthroscopic rotator cuff repair using 2 rows of fixation: Minimum 2-year follow-up. *Am J Sports Med* 2006;34:1899-1905.
- Nelson CO, Sileo MJ, Grossman MG, Serra-Hsu F. Single-row modified Mason-Allen versus double-row arthroscopic rotator cuff repair: A biomechanical and surface area comparison. *Arthroscopy* 2008;24:941-948.
- Millett PJ, Mazzocca A, Guanche CA. Mattress double anchor footprint repair: A novel, arthroscopic rotator cuff repair technique. *Arthroscopy* 2004;20:875-879.
- Franceschi F, Longo UG, Ruzzini L, Rizzello G, Maffulli N, Denaro V. The Roman Bridge: A "double pulley-suture bridges" technique for rotator cuff repair. *BMC Musculoskelet Disord* 2007;8:123.
- Grasso A, Milano G, Salvatore M, Falcone G, Deriu L, Fabriciani C. Single-row versus double-row arthroscopic rotator cuff repair: A prospective randomized clinical study. *Arthroscopy* 2009;25:4-12.
- Lafosse L, Brzoska R, Toussaint B, Gobeze R. The outcome and structural integrity of arthroscopic rotator cuff repair with use of the double-row suture anchor technique. Surgical technique. *J Bone Joint Surg Am* 2008;90:275-286 (Suppl 2, pt 2).
- Frank JB, ElAttrache NS, Dines JS, Blackburn A, Crues J, Tibone JE. Repair site integrity after arthroscopic transosseous-equivalent suture-bridge rotator cuff repair. *Am J Sports Med* 2008;36:1496-1503.
- Yanke A, Provencher MT, Cole BJ. Arthroscopic double-row and "transosseous-equivalent" rotator cuff repair. *Am J Orthop* 2007;36:294-297.
- Tuoheti Y, Itoi E, Yamamoto N, et al. Contact area, contact pressure, and pressure patterns of the tendon-bone interface after rotator cuff repair. *Am J Sports Med* 2005;33:1869-1874.