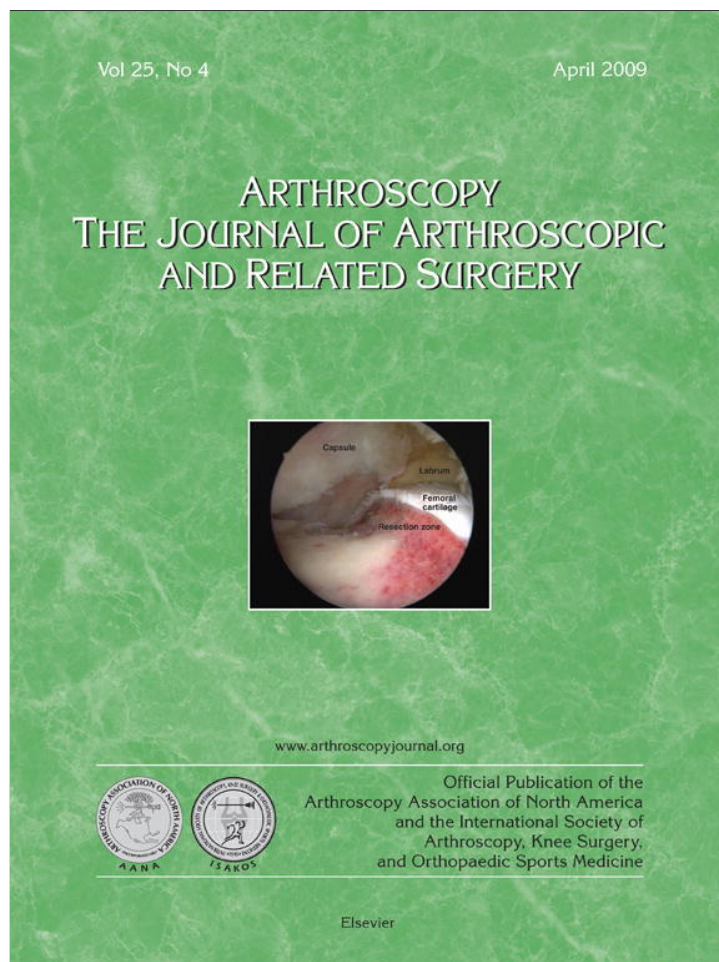


Provided for non-commercial research and education use.  
Not for reproduction, distribution or commercial use.



This article appeared in a journal published by Elsevier. The attached copy is furnished to the author for internal non-commercial research and education use, including for instruction at the authors institution and sharing with colleagues.

Other uses, including reproduction and distribution, or selling or licensing copies, or posting to personal, institutional or third party websites are prohibited.

In most cases authors are permitted to post their version of the article (e.g. in Word or Tex form) to their personal website or institutional repository. Authors requiring further information regarding Elsevier's archiving and manuscript policies are encouraged to visit:

<http://www.elsevier.com/copyright>

## Technical Note

# Arthroscopic Decompression of the Suprascapular Nerve at the Spinoglenoid Notch and Suprascapular Notch Through the Subacromial Space

Neil Ghodadra, M.D., Shane J. Nho, M.D., M.S., Nikhil N. Verma, M.D., Stefanie Reiff, B.A., Dana P. Piasecki, M.D., Matthew T. Provencher, M.D., and Anthony A. Romeo, M.D.

---

**Abstract:** Suprascapular nerve entrapment can cause disabling shoulder pain. Suprascapular nerve release is often performed for compression neuropathy and to release pressure on the nerve associated with arthroscopic labral repair. This report describes a novel all-arthroscopic technique for decompression of the suprascapular nerve at the suprascapular notch or spinoglenoid notch through a subacromial approach. Through the subacromial space, spinoglenoid notch cysts can be visualized between the supraspinatus and infraspinatus at the base of the scapular spine. While viewing the subacromial space through the lateral portal, the surgeon can use a shaver through the posterior portal to decompress a spinoglenoid notch cyst at the base of the scapular spine. To decompress the suprascapular nerve at the suprascapular notch, a shaver through the posterior portal removes the soft tissue on the acromion and distal clavicle to expose the coracoclavicular ligaments. The medial border of the conoid ligament is identified and followed to its coracoid attachment. The supraspinatus muscle is retracted with a blunt trocar placed through an accessory Neviaser portal. The transverse scapular ligament, which courses inferior to the suprascapular artery, is sectioned with arthroscopic scissors, and the suprascapular nerve is decompressed. **Key Words:** Arthroscopy—Suprascapular nerve—Transverse scapular ligament—Suprascapular notch—Rotator cuff—Shoulder.

---

Suprascapular nerve (SSN) entrapment is a cause of shoulder pain and weakness.<sup>1,2</sup> Suprascapular neuropathy is infrequent, causing only 1% to 2% of diagnoses for shoulder pain.<sup>3</sup> It occurs at either the suprascapular notch, resulting in weakness and atrophy of both the infraspinatus and the supraspinatus, or at the

spinoglenoid notch, resulting in only infraspinatus weakness.<sup>4</sup> Constraint of the nerve is commonly caused by its course through the suprascapular notch under the transverse scapular ligament (TSL) or through the spinoglenoid notch under the spinoglenoid ligament, as well as compression by supraglenoid and paralabral cysts.<sup>4,6</sup> Although conservative treatment such as physical therapy can be recommended for SSN entrapment, it is commonly only successful in cases of overuse and is not successful in cases of nerve compression or space-occupying lesions, which require surgery for pain relief.<sup>5,7</sup> Whereas pain relief after surgery has been consistent, the return of muscle strength and shoulder function is less predictable.<sup>4,8</sup>

The literature reports the advantages of the arthroscopic techniques over the traditional open procedure for SSN decompression.<sup>1,5,6,9-12</sup> Similar to other reported arthroscopic techniques to decompress the SSN

---

*From the Section of Sports Medicine, Department of Orthopedic Surgery, Rush University Medical Center, Rush Medical College of Rush University, Chicago, Illinois, U.S.A.*

*N.N.V. is a consultant for Smith & Nephew. A.A.R. is a consultant for Arthrex. The authors report no conflict of interest.*

*Address correspondence and reprint requests to Neil Ghodadra, M.D., Rush University Medical Center, 1725 W Harrison St, Suite 1063, Chicago, IL 60612, U.S.A. E-mail: Ghodadra.neil@gmail.com*

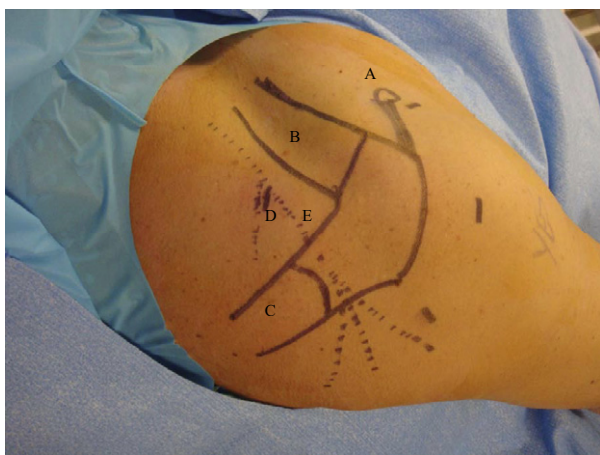
© 2009 by the Arthroscopy Association of North America  
0749-8063/09/2504-8541\$36.00/0  
doi:10.1016/j.arthro.2008.10.024

at the suprascapular notch, our technique relies on a subacromial approach and direct visualization of the relevant anatomy of the coracoclavicular (CC) ligaments, suprascapular neurovascular structures, and TSL.<sup>1,9,10,13-15</sup> In contrast to other described techniques of arthroscopic SSN decompression at the spinoglenoid notch, our surgical technique describes SSN decompression through the subacromial space.<sup>16-19</sup> This technique allows direct visualization of the medial neck of the glenoid and helps avoid complications of iatrogenic SSN nerve injury from overly aggressive medial capsule dissection through the glenohumeral joint. With a thorough understanding of shoulder anatomy, the orthopaedic surgeon should be able to identify the spinoglenoid notch and the suprascapular notch in the subacromial space and decompress the SSN without injury to the nerve or surrounding structures. The purpose of this article is to provide our surgical technique to safely and successfully decompress the SSN at the suprascapular notch or the spinoglenoid notch through the glenohumeral joint and subacromial space.

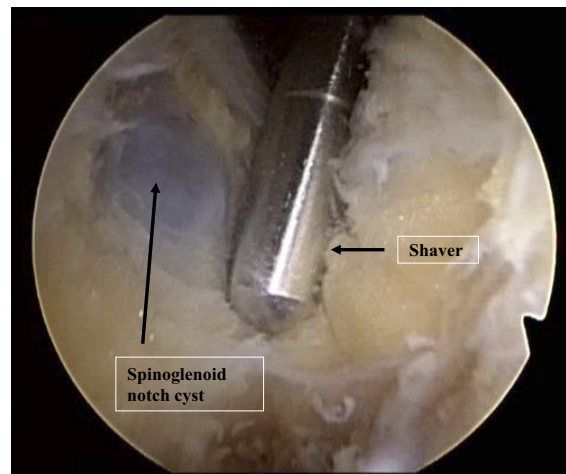
## SURGICAL TECHNIQUE

### Patient Positioning

We prefer to place the patient in the beach-chair position, but patients may be positioned in the lateral decubitus position in cases of concomitant SLAP repair. After standard preparation and draping, the acromion, distal clavicle, and coracoid process, as well as the course of the SSN, are outlined with a marking



**FIGURE 1.** Right shoulder of patient in lateral decubitus position. Drawn landmarks include the (A) coracoid, (B) clavicle, (C) scapular spine, (D) suprascapular notch, and (E) course of the SSN marked with a dotted line.



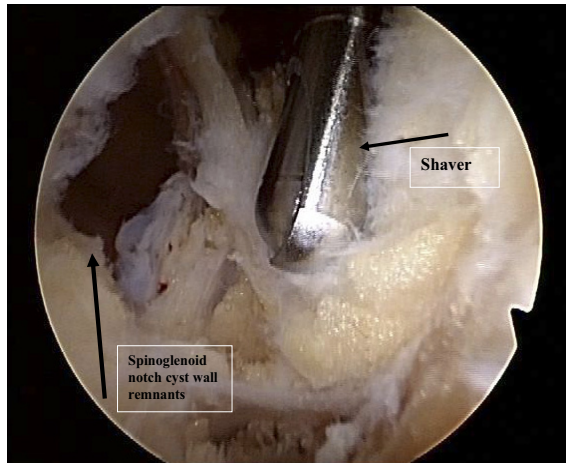
**FIGURE 2.** Left shoulder of patient in beach-chair position, showing arthroscopic visualization of spinoglenoid cyst through glenohumeral joint. The arthroscope is placed in the anterior portal, and the mechanical shaver is placed through the posterior portal.

pen (Fig 1). A posterior portal is created approximately 3 cm inferior to and in line with the posterolateral acromion. The 30° arthroscope is inserted through this portal, and diagnostic glenohumeral arthroscopy is performed. An initial anterior portal is created high in the rotator interval with an outside-in technique after localization with an 18-gauge spinal needle. Hemostasis is critical to visualization during the procedure and can be enhanced by maintaining adequate arthroscopic pump pressure (approximately 50 mm Hg) and relative hypotensive anesthesia (systolic blood pressure of about 100 mm Hg).

### Spinoglenoid Notch

In cases of a SLAP lesion that requires repair, the spinoglenoid notch is accessed through the glenohumeral joint. We recommend repairing the SLAP lesion before performing the paralabral cyst decompression. Once the SLAP repair is complete, the arthroscope is placed in the anterior portal. The posterior-superior capsular release is performed with a mechanical shaver between the 9-o'clock and 12-o'clock positions, and debridement should be performed clearly away from the posterior band of the inferior glenohumeral ligament complex. The raphe between the supraspinatus and infraspinatus is identified and followed medially. At this point, the prominence of the cyst can be seen directly on the scapula (Fig 2). The cyst is decompressed with the mechanical shaver, and synovial fluid emanating from the cavity is visible. The mechanical shaver is used to remove part of the

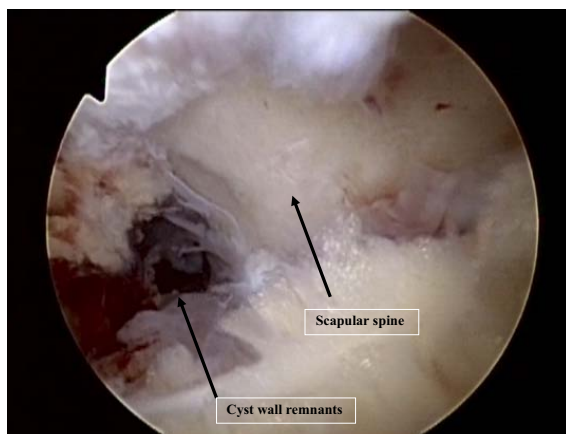




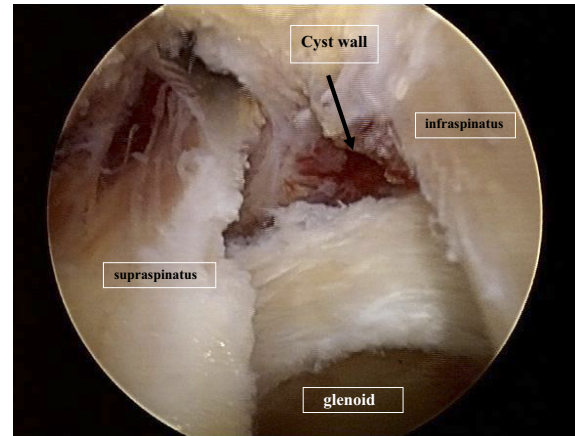
**FIGURE 3.** Left shoulder of patient in beach-chair position, showing arthroscopic visualization of cystic wall remnants after debridement of spinoglenoid cyst with shaver placed through posterior portal.

cyst wall to limit the possibility of recurrence. The decompression is complete when no additional cystic wall remnants or fluid can be detected (Fig 3).

If inspection of the glenohumeral joint does not show a capsule or labral tear, the spinoglenoid notch cyst is decompressed from the subacromial space. The arthroscopic instrumentation is then placed in the subacromial space by use of the posterior portal and a lateral portal. All soft tissue is removed from the undersurface of the acromion and the bursal surface of the rotator cuff. At this point, the arthroscope is directed posteriorly and medially to identify the separate muscle bellies of the supraspinatus and the infraspi-



**FIGURE 4.** Left shoulder of patient in beach-chair position, showing arthroscopic visualization of spinoglenoid cyst in typical location at base of scapular spine.

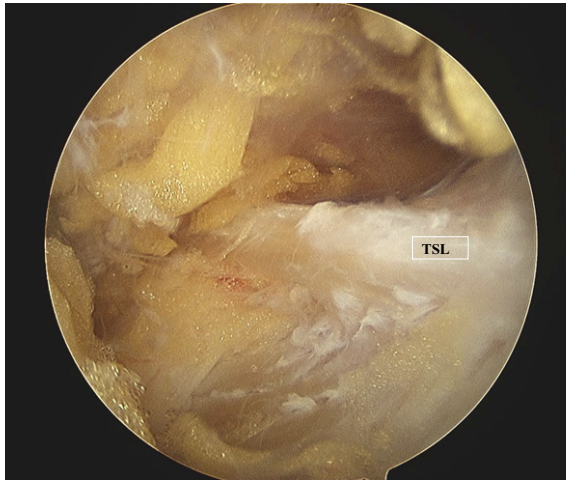


**FIGURE 5.** Left shoulder of patient in beach-chair position, showing arthroscopic visualization of spinoglenoid cyst cavity after debridement through subacromial space. The arthroscope is placed into the subacromial space through the lateral portal, and the space between the supraspinatus and infraspinatus is visualized.

natus. The scapular spine is visualized and demarcates the medial boundary of the dissection (Fig 4). A probe can be used to palpate the posterior aspect of the glenoid, which defines the anterior boundary, and the cyst can sometimes be localized between the scapular spine and the posterior glenoid. The mechanical shaver is used to debride the soft tissue and further expose the spinoglenoid notch cyst (Fig 5). The mechanical shaver is advanced from anterior to posterior, but this must be done with caution to avoid injury to the SSN. The tip of the mechanical shaver can be used to intermittently palpate the cyst. The SSN is located at the base of the scapular spine, and therefore the mechanical shaver should not be used near the spine. If the cyst is not palpable, the mechanical shaver can be carefully advanced until cyst fluid is visible.

### Suprascapular Notch

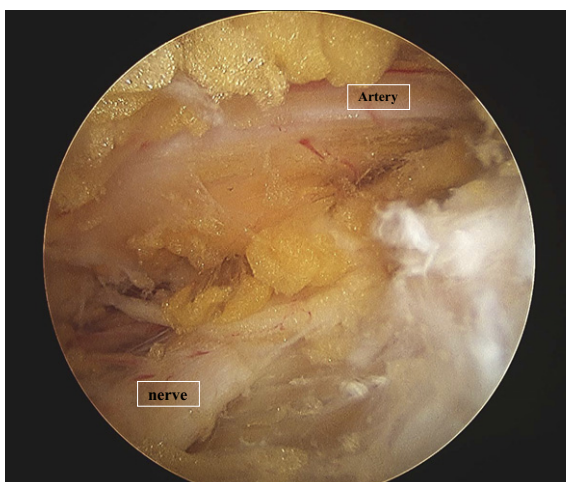
To decompress the SSN at the suprascapular notch, the arthroscope is placed in the lateral portal, and the shaver is introduced via the posterior portal. The dissection proceeds medial to the acromioclavicular joint to allow identification of the CC ligaments. The posterior aspect of the CC ligaments is dissected, and the conoid ligament is identified medially, along with the anterior border of the supraspinatus muscle. Again, care must be taken during the dissection to maintain continuous hemostasis. Once the anterior edge of the supraspinatus is adequately visualized, an accessory portal is created about 2 cm medial to a standard Neviaser portal, anterior to the scapular spine. This



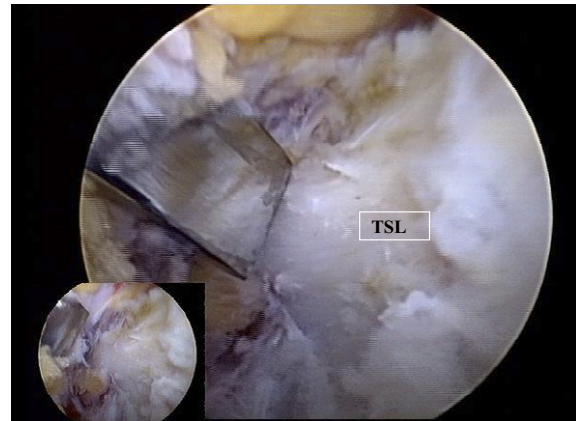
**FIGURE 6.** Right shoulder, lateral view, showing arthroscopic visualization of TSL through lateral portal.

portal is created under spinal needle localization, and a blunt trocar is introduced. The trocar is then used for further blunt dissection and for posterior retraction of the supraspinatus muscle belly.

By use of the shaver via the posterior portal and blunt dissection with the trocar, the base of the conoid ligament is identified. The base marks the lateral insertion of the TSL, which can now be identified running approximately perpendicular to the CC ligaments (Fig 6). By use of the blunt trocar, the SSN can be identified and protected during sectioning of the ligament (Fig 7). The artery is generally visualized run-



**FIGURE 7.** Right shoulder, lateral view, showing arthroscopic visualization of suprascapular artery running superior to SSN through lateral portal.



**FIGURE 8.** Right shoulder with patient in beach-chair position, showing debridement of ossified TSL with osteotome.

ning superior to the TSL in most cases, and care should be taken during dissection in this area to avoid excessive bleeding, which may impair visualization. However, we are unaware of any significant sequelae if the artery is inadvertently injured during the dissection, and bleeding can generally be controlled with radiofrequency coagulation. A second Neviaser portal is created under spinal needle localization to allow access to the TSL. This portal is placed in a standard Neviaser position at the junction of the scapular spine and posterior aspect of the acromioclavicular joint. Under direct visualization, the surgeon then uses arthroscopic scissors or a punch to section the ligament while retracting the SSN with the blunt trocar. Rarely, there are cases in which the transverse ligament is ossified, and a quarter-inch osteotomy can be used to resect the ossified ligament (Fig 8).

## DISCUSSION

With the introduction of new arthroscopic techniques to release the TSL, a thorough understanding of the anatomy of the SSN is important to provide for safe, reproducible decompression techniques. The SSN originates from the upper trunk of the brachial plexus with contributions from the C4, C5, and C6 nerve roots. The SSN courses deep to the omohyoid and trapezius muscles before traveling to the suprascapular notch with the suprascapular artery. At the suprascapular notch, the SSN passes underneath the TSL and provides 2 motor branches to the supraspinatus, whereas the suprascapular artery courses over the TSL. The nerve then passes deep to the supraspi-

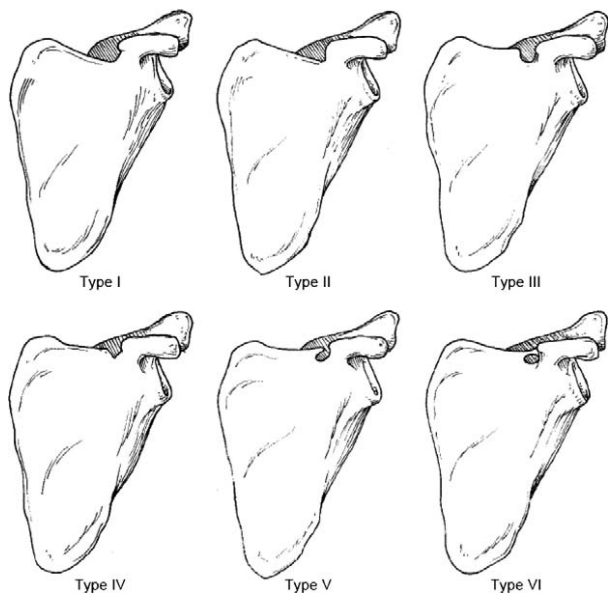


FIGURE 9. Suprascapular notch. Rengachary et al.<sup>20</sup> described 6 types of suprascapular notch: type I, depression (8%); type II, shallow V-shaped (31%); type III, U-shaped (48%); type IV, deep V-shaped (3%); type V, type III with partial ossification of ligament (6%); and type VI, complete ossification of ligament. (Reprinted with permission.<sup>20</sup>)

natus, through the spinoglenoid notch, and terminates in the muscle belly of the infraspinatus (Fig 1).

At the spinoglenoid notch, the SSN can be constrained by the inferior transverse suprascapular ligament or by a ganglion cyst.<sup>5</sup> At the suprascapular notch, the SSN faces entrapment by the TSL and the shape of the notch itself. Six different classifications of suprascapular notch anatomy were originally defined by Rengachary et al.<sup>20</sup> (Fig 9). The type I notch is defined as lacking a discrete notch. Type II is a wide V-shaped notch, whereas type III is a wide U-shaped notch. Types IV and V are a narrower V-shaped notch and a U-shaped notch with partial ossification of the transverse suprascapular ligament, respectively. Finally, the type VI notch is defined as a completely ossified transverse suprascapular ligament.

The type VI notch, which occurs approximately 4% to 12.5% of the time in cases of SSN entrapment, is composed of a calcified ligament that reduces the space for the SSN within the notch, thus compressing and aggravating the nerve.<sup>9,20,21</sup> Whereas the other types of notches involve ligament release and potential burring of the notch to widen the path for the SSN, the type VI notch provides the added complication of the ossified ligament. We prefer to use an osteotome to resect the ossified TSL, but other authors have described using a Kerrison rongeur.<sup>13</sup>

Traditionally, SSN entrapment is treated with an open decompression at both the spinoglenoid notch and the suprascapular notch. A posterior incision is used to expose the scapular spine and then the spinoglenoid ligament at the spinoglenoid notch.<sup>4</sup> The suprascapular notch decompression procedure involves either an incision along the scapular spine or a muscle-splitting technique in which the trapezius is split in line with the muscle fibers, localizing the nerve for release.<sup>1,4</sup> More recently, an arthroscopic approach for both spinoglenoid and suprascapular notch decompression has been favored. Most commonly, decompressions of ganglion cysts occur at the spinoglenoid notch, where landmarks such as the acromioclavicular joint, conoid ligament, and coracoid process can be used to locate the SSN without endangering the spinal accessory nerve at the suprascapular notch.<sup>4,10</sup> Open dissections of cadavers after arthroscopic SSN decompressions show that no nerve or arterial damage is inflicted by this procedure.<sup>6</sup>

Although the arthroscopic procedure is technically difficult, it has been shown to be safe, reproducible, and favorable over the open technique.<sup>1,5,6,9-12</sup> To begin, the arthroscopic technique makes it easier to identify and distinguish the SSN nerve from the nearby artery and ligament because of the magnification of the arthroscope.<sup>1,10</sup> This procedure also makes it possible to assess other comorbid injuries such as labral tears.<sup>5,9</sup> Simultaneously decompressing the SSN and fixing a labral tear, which is not possible in the open technique, has been shown to reduce recurrence of nerve entrapment.<sup>5,9</sup> Finally, the less invasive arthroscopy does not involve detaching or splitting the trapezius muscle, which results in less pain for the patient.<sup>1</sup> This allows the patient to start rehabilitation sooner and thus recover faster.<sup>2,5</sup> The arthroscopic technique has been reported to have success in relieving pain and returning muscle strength and shoulder function equal to that of the open technique.<sup>2,4</sup>

In comparison to other described techniques of arthroscopic decompression of the SSN, our technique offers varied risks and benefits<sup>1,9,10,14,17,19,22</sup> (Tables 1 and 2). With our technique, the spinoglenoid notch cyst can be directly visualized through the subacromial space,<sup>5</sup> and dissection of the capsule along the medial neck of the glenoid can be avoided. In contrast to other reports, we prefer to decompress the spinoglenoid notch cyst after repair of a SLAP lesion.<sup>9,16,19</sup> Decompression of the cyst through the torn labrum exposes the labrum and SSN to additional risk because inadequate visualization of the medial neck of the glenoid and overlying SSN can lead to iatrogenic



injury. With direct visualization of the cyst through the subacromial space, the spinoglenoid cyst can be carefully decompressed. With a concomitant rotator cuff tear, our technique provides the surgeon with a facile method to visualize and decompress the cyst through the same portals that can be used to repair the rotator cuff. With this technique, however, the arthroscopist must be able to identify the raphe between the supraspinatus and infraspinatus to locate the spinoglenoid notch without injuring the rotator cuff muscle bellies. A thorough diagnostic arthroscopy must be performed before performing our described method of spinoglenoid notch cyst decompression to rule out a concomitant SLAP tear. Our preferred method for release of the TSL is similar to other reported techniques that rely on visualization of the CC ligaments through the subacromial space.<sup>1,10,13,14</sup> For decompression of the SSN at the suprascapular notch, we recommend careful retraction of the fat pad and suprascapular artery with blunt trocars inserted through separate Neviaser portals. To release an ossified TSL, we prefer to use an osteotome, whereas other described techniques report the use of Kerrison rongeurs or burs.<sup>1,13</sup>

Our surgical technique should enable the orthopaedic surgeon to identify the SSN at both the suprascapular notch and the spinoglenoid notch via the subacro-

**TABLE 1.** *Advantages and Risks of Our SSN Decompression Technique*

Advantages	Risks
Direct visualization of spinoglenoid notch	Requires identification of raphe between supraspinatus and infraspinatus
Does not require 70° arthroscope	Missed SLAP tear
No need for accessory posterolateral portal	Overly aggressive use of osteotome for ossified TSL
Performed through subacromial space to allow decreased operative time	Injury to muscle bellies of supraspinatus or infraspinatus
Decreased chance of inadvertent injury to medial capsule and labrum compared with glenohumeral approach	Cyst cavity may not always be visualized depending on its chronicity
Use of dual Neviaser portals allows direct approach to dissection of deep surface of CC ligaments and SSN	

**TABLE 2.** *Surgical Pearls and Complications During SSN Decompression*

Surgical Tips/Pearls	Complications to Avoid
Rule out concomitant glenohumeral pathology with diagnostic arthroscope	Incomplete cyst wall decompression
Repair SLAP tear before cyst decompression	Failure to diagnose concomitant SLAP tear
Use 30° arthroscope	Overly aggressive use of osteotome for bony TSL
Identify raphe between supraspinatus and infraspinatus	Failure to locate CC ligaments before visualization of TSL
Use blunt trocar to retract infraspinatus and avoid injury to SSN branch to infraspinatus	Injury to SSN from aggressive medial capsular dissection
Visualize SSN as it courses under TSL	
Identify and debride entire cyst wall	
Keep pump pressure high to decrease bleeding	
Use blunt trocar to retract suprascapular artery	

mial space. Arthroscopic decompression of the SSN at the spinoglenoid notch has been described through the glenohumeral joint with a posterior and superior capsulotomy. We prefer this approach in cases requiring a simultaneous SLAP repair. In cases without an obvious tear in the labrum or capsule, we prefer to decompress the paralabral cyst at the spinoglenoid notch through the subacromial space so that the cystic fluid may drain into the subacromial space should fluid continue to collect. The subacromial approach should, in theory, decrease the possibility of recurrence, but clinical follow-up comparing these 2 techniques needs to be performed to determine the likelihood of recurrence.

**CONCLUSIONS**

Compression of the SSN at the transverse scapular notch or spinoglenoid notch has important clinical implications with regard to supraspinatus and infraspinatus atrophy and weakness. All arthroscopic techniques of SSN release have recently been described and offer several advantages over the traditional open method. This report describes a simplified subacro-

mial arthroscopic technique for decompression of the SSN at the suprascapular notch and spinoglenoid notch while providing the surgeon with a facile, effective method to concomitantly evaluate and treat comorbid shoulder pathology.

## REFERENCES

- Lafosse L, Tomasi A, Corbett S, Baier G, Willems K, Gobezie R. Arthroscopic release of suprascapular nerve entrapment at the suprascapular notch: Technique and preliminary results. *Arthroscopy* 2007;23:34-42.
- Lee BC, Yegappan M, Thiagarajan P. Suprascapular nerve neuropathy secondary to spinoglenoid notch ganglion cyst: Case reports and review of literature. *Ann Acad Med Singapore* 2007;36:1032-1035.
- Zehetgruber H, Noske H, Lang T, Wurnig C. Suprascapular nerve entrapment. A meta-analysis. *Int Orthop* 2002;26:339-343.
- Piasecki DP, Romeo AA, Nicholson GP, Bach BR. Suprascapular neuropathy. *J Am Acad Orthop Surg*. In press.
- Westerheide KJ, Dopirak RM, Karzel RP, Snyder SJ. Suprascapular nerve palsy secondary to spinoglenoid cysts: Results of arthroscopic treatment. *Arthroscopy* 2006;22:721-727.
- Soubeyrand M, Bauer T, Billot N, Lortat-Jacob A, Gicquelet R, Hardy P. Original portals for arthroscopic decompression of the suprascapular nerve: An anatomic study. *J Shoulder Elbow Surg* 2008;17:616-623.
- Antoniou J, Tae SK, Williams GR, Bird S, Ramsey ML, Iannotti JP. Suprascapular neuropathy. Variability in the diagnosis, treatment, and outcome. *Clin Orthop Relat Res* 2001: 131-138.
- Romeo AA, Rotenberg DD, Bach BR Jr. Suprascapular neuropathy. *J Am Acad Orthop Surg* 1999;7:358-367.
- Hosseini H, Agneskirchner JD, Troger M, Lobenhoffer P. Arthroscopic release of the superior transverse ligament and SLAP refixation in a case of suprascapular nerve entrapment. *Arthroscopy* 2007;23:1134.e1-1134.e4. Available online at [www.arthroscopyjournal.org](http://www.arthroscopyjournal.org).
- Bhatia DN, de Beer JF, van Rooyen KS, du Toit DF. Arthroscopic suprascapular nerve decompression at the suprascapular notch. *Arthroscopy* 2006;22:1009-1013.
- Lichtenberg S, Magosch P, Habermeyer P. Compression of the suprascapular nerve by a ganglion cyst of the spinoglenoid notch: The arthroscopic solution. *Knee Surg Sports Traumatol Arthrosc* 2004;12:72-79.
- Weinfeld AB, Cheng J, Nath RK, Basaran I, Yuksel E, Rose JE. Topographic mapping of the superior transverse scapular ligament: A cadaver study to facilitate suprascapular nerve decompression. *Plast Reconstr Surg* 2002;110:774-779.
- Agrawal V. Arthroscopic decompression of a bony suprascapular foramen. *Arthroscopy* 2009;25:325-328.
- Barwood SA, Burkhart SS, Lo IK. Arthroscopic suprascapular nerve release at the suprascapular notch in a cadaveric model: An anatomic approach. *Arthroscopy* 2007;23:221-225.
- Costouros JG, Porramatikul M, Lie DT, Warner JJ. Reversal of suprascapular neuropathy following arthroscopic repair of massive supraspinatus and infraspinatus rotator cuff tears. *Arthroscopy* 2007;23:1152-1161.
- Youm T, Matthews PV, El Attrache NS. Treatment of patients with spinoglenoid cysts associated with superior labral tears without cyst aspiration, debridement, or excision. *Arthroscopy* 2006;22:548-552.
- Werner CM, Nagy L, Gerber C. Combined intra- and extra-articular arthroscopic treatment of entrapment neuropathy of the infraspinatus branches of the suprascapular nerve caused by a periglenoid ganglion cyst. *Arthroscopy* 2007;23:328.e1-328.e3. Available online at [www.arthroscopyjournal.org](http://www.arthroscopyjournal.org).
- Cummins CA, Bowen M, Anderson K, Messer T. Suprascapular nerve entrapment at the spinoglenoid notch in a professional baseball pitcher. *Am J Sports Med* 1999;27:810-812.
- Chen AL, Ong BC, Rose DJ. Arthroscopic management of spinoglenoid cysts associated with SLAP lesions and suprascapular neuropathy. *Arthroscopy* 2003;19:e15-e21. Available online at [www.arthroscopyjournal.org](http://www.arthroscopyjournal.org).
- Rengachary SS, Burr D, Lucas S, Brackett CE. Suprascapular entrapment neuropathy: A clinical, anatomical, and comparative study. Part 3: Comparative study. *Neurosurgery* 1979;5: 452-455.
- Natsis K, Totlis T, Tsikaras P, Appell HJ, Skandalakis P, Koebke J. Proposal for classification of the suprascapular notch: A study on 423 dried scapulas. *Clin Anat* 2007;20:135-139.
- Barber FA. Percutaneous arthroscopic release of the suprascapular nerve. *Arthroscopy* 2008;24:236.e1-236.e4. Available online at [www.arthroscopyjournal.org](http://www.arthroscopyjournal.org).