

American Journal of Sports Medicine

<http://ajs.sagepub.com>

Rotator Cuff Degeneration: Etiology and Pathogenesis

Shane J. Nho, Hemang Yadav, Michael K. Shindle and John D. MacGillivray
Am. J. Sports Med. 2008; 36; 987 originally published online Apr 15, 2008;
DOI: 10.1177/0363546508317344

The online version of this article can be found at:
<http://ajs.sagepub.com/cgi/content/abstract/36/5/987>

Published by:

 SAGE Publications

<http://www.sagepublications.com>

On behalf of:



[American Orthopaedic Society for Sports Medicine](#)

Additional services and information for *American Journal of Sports Medicine* can be found at:

Email Alerts: <http://ajs.sagepub.com/cgi/alerts>

Subscriptions: <http://ajs.sagepub.com/subscriptions>

Reprints: <http://www.sagepub.com/journalsReprints.nav>

Permissions: <http://www.sagepub.com/journalsPermissions.nav>

Citations (this article cites 52 articles hosted on the
SAGE Journals Online and HighWire Press platforms):
<http://ajs.sagepub.com/cgi/content/abstract/36/5/987#BIBL>

Rotator Cuff Degeneration

Etiology and Pathogenesis

Shane J. Nho,* MD, Hemang Yadav, MBBS, Michael K. Shindle, MD, and John D. MacGillivray, MD

From the Hospital for Special Surgery, New York, New York

By virtue of its anatomy and function, the rotator cuff is vulnerable to considerable morbidity, often necessitating surgical intervention. How we intervene is governed by our understanding of the pathological mechanisms in cuff disease. These factors can be divided into those extrinsic to the rotator cuff (impingement, demographic factors) and those intrinsic to the cuff (age-related degeneration, hypovascularity, inflammation, and oxidative stress, among others). In an era where biologic interventions are increasingly being investigated, our understanding of these mechanisms is likely to become more important in designing effective new interventions. Here we present a literature review summarizing our current understanding of the pathophysiological mechanisms underlying rotator cuff degeneration.

Keywords: rotator cuff tears; rotator cuff degeneration; degenerative microtrauma

Rotator cuff degeneration is a very common orthopaedic condition, and there are multiple factors that eventually lead to a full-thickness rotator cuff tear. Traditionally, these causative mechanisms have been subdivided into extrinsic and intrinsic factors. Extrinsic factors predominantly reflect demographic and anatomic variables that interact to contribute to rotator cuff damage. Intrinsic factors are where the pathologic changes lie predominantly within the rotator cuff muscle itself. The critical process within intrinsic disease is likely degenerative in nature, and we present current theories emphasizing the possible factors that could be contributing to this degenerative process. In many patients, it is likely their pathologic abnormality is a byproduct of the interaction between both intrinsic and extrinsic factors. The future of the treatment of rotator cuff tears will likely involve biologic modulation of the degenerative process to prevent rotator cuff tears or optimization of the tendon repair with delivery of local adjuvants, and an understanding of the underlying disease process will facilitate the rationale and development of potential treatment modalities.

EXTRINSIC FACTORS

Impingement and Acromial Shape

Neer and Poppen³⁵ first postulated the impingement theory on the basis of intraoperative observations in more than 400 patients with cuff tears. They concluded that 95% of all rotator cuff tears were initiated by impingement-associated lesions, with the anterior third of the acromion principally responsible. The degree of such impingement was suggested by Bigliani et al⁵ to be related to acromial shape. They noted that the shape of the acromion varied in its sagittal plane, with 3 broad classifications of acromions. Type I, or flat acromions, were seen in 17% of cuff tears; type II, or curved acromions, in 43% of tears; and type III, or hooked acromions, in 39% of cadaveric full-thickness cuff tears. MacGillivray et al³⁰ demonstrated that laterally sloping acromions were also positively correlated with cuff disease. Wang et al⁵¹ analyzed more than 200 patients and showed that the success of conservative management decreased with changes in acromion shapes: type I acromions responded in 89% of cases, type II in 73% of cases, and type III in just 58.3% ($P < .008$).

Early studies suggested that acromial shape was age-stable and, consequently, a predominantly congenital trait.³⁶ Wang and Shapiro,⁵² however, examined the acromial morphologic characteristics in a large cohort of patients and demonstrated a statistical progression from type I to type III acromion with age. Such an age-related progression would tie in with the epidemiological evidence

*Address correspondence to Shane J. Nho, The Hospital for Special Surgery, 535 East 70th Street, York, NY 10021 (e-mail: nhos@hss.edu).
No potential conflict of interest declared.

linking age with cuff tear prevalence. An explanation of how such a progression could take place was suggested by Shah et al,⁴³ who provided histological and radiographic evidence for acromial shape being acquired through traction forces rather than simply congenital. Significantly, this implies that acromial variations and impingement are secondary to another primary intrinsic initiating factor. Whether acromial shape truly is congenital or acquired remains controversial.

Neer's hypothesis of impingement as the crucial etiological factor in rotator lesions has led to subacromial decompression being accepted as an important and generally very successful treatment for relieving shoulder pain associated with tendinopathy. However, Flatow et al¹³ suggested that a superior stability of the shoulder in patients with massive tears was achieved via an intact coracoacromial arch, and therefore not all patients would necessarily benefit from an acromioplasty operation. Hyvonen et al²³ analyzed 96 patients treated with acromioplasty for impingement and found that despite the decompression, 20% still experienced a rotator cuff tear in the next 9 years. While it could be argued that the damage in these cases had already been done before the time of the repair, it does question the precise importance of impingement in the cause of these injuries. A histology study by Ko et al²⁵ suggests a middle ground. They provide evidence for articular side tears being predominantly derived from degenerative changes and bursal side tears being derived from trauma secondary to impingement. They conclude by advocating acromioplasty in all bursal-side partial tears and in articular-side tears only if evidence of an acromial spur was present.

Demographic Factors

The relationship between epidemiological variables and rotator cuff lesions is a difficult one with relatively little quality data available. Increasing age is the best-correlated independent variable and is discussed more fully later.

A well-documented theory is the association between mechanical overuse and cuff tearing. Consistent with such an association, there is more often symptomatic disease in dominant arms than in nondominant arms.⁵³ However, 36% of those with a full-thickness symptomatic cuff tear had a full-thickness tear of the contralateral nondominant side. This likelihood rose to 50% in those older than 66 years of age. Another study examining the possible role of overuse in rotator cuff injury showed that 28% of symptomatic patients had a full-thickness tear in their nondominant arm *only*.²⁰ When patients were asked about the levels of their activity, 70% of full-thickness tears occurred in sedentary individuals who did light work only. While these numbers certainly suggest that mechanical factors might have a role in contributing to cuff disease, they are likely to be only one of several factors acting in concert within susceptible individuals. This is discussed in more detail below with the degeneration-microtrauma model.

Smoking has also been associated with poorer outcomes in patients with rotator cuff disease, particularly with regard to tendon healing and repair. Smokers are less likely to respond favorably to cuff repair operations, with significantly reduced

postoperative function and patient satisfaction, and increased pain scores relative to nonsmoker controls.³¹ In a rat animal model study, Galatz et al¹⁵ demonstrated that a significant factor in this regard could be the deleterious effects of nicotine on tendon healing. They implanted osmotic pumps in 72 rats, delivering either nicotine or saline solution to the area around the cuff repair. At the 56-day endpoint, the nicotine group showed increased persistence of inflammatory markers, reduced mechanical properties, and reduced collagen concentrations relative to the saline controls. Although the nicotine concentrations are likely to be supraphysiological in this instance, the effects of nicotine demonstrated in this model may certainly apply to humans. Indeed, other factors that reduce tendon healing, such as diabetes mellitus, are also associated with rotator cuff lesions.⁸

Summary of Extrinsic Factors

Rotator cuff disease may be initiated, or at least propagated, by factors extrinsic to the cuff itself. These factors are broadly grouped into anatomical and environmental. Of the anatomical factors, the best characterized is acromial morphologic characteristics. Hooked, curved, and laterally sloping acromions are strongly associated with cuff tears and may contribute by causing tractional damage to the tendon. Patients with such anatomy are likely to benefit most from a subacromial decompression, particularly if their tear is bursal-side in origin. Conversely, flat acromions may have a minimal contribution to cuff disease and consequently are often best treated conservatively. The development of these different acromial shapes is likely both congenital and acquired. With acquired causes, only age has been positively correlated to progression from a flat to a curved or hooked acromion. Frequency, intensity, and nature of mechanical activities, including sports, may be responsible; however, data in this regard are lacking. Moreover, a progression to a hooked acromion may simply be an adaptation to an already damaged, poorly balanced rotator cuff that is creating increasing stress on the coracoacromial arch. Other anatomical factors that may have significance include *os acromiale* and acromial spurs, which have been well documented elsewhere.⁴ Environmental factors implicated include increasing age, shoulder overuse, smoking, and any medical condition that impairs the inflammatory and healing response such as diabetes mellitus. However, in general, there is a lack of in-depth epidemiological data on this condition, likely due to its multifactorial, insidious, and often asymptomatic presentation.

INTRINSIC FACTORS

Intrinsic factors encompass the range of mechanisms that occur within the rotator cuff itself. Chief among these is a degenerative-microtrauma model, which supposes that age-related tendon damage compounded by chronic microtrauma results in partial tendon tears that then develop into full rotator cuff tears. As a result of repetitive microtrauma in the setting of a degenerative rotator cuff tendon, inflammatory mediators alter the local environment,^{38,45}

and oxidative stress induces tenocyte apoptosis^{10,54-56} causing further rotator cuff tendon degeneration. The neural theory suggests neural overstimulation leads to the recruitment of inflammatory cells and may also contribute to tendon degeneration.⁴¹

Degeneration-Microtrauma Theory

Rotator Cuff Tendon Degeneration. Epidemiological studies certainly support a relationship between age and cuff tear prevalence. Tempelhof et al⁴⁷ found a positive correlation between age and cuff tears on ultrasound examination of more than 400 asymptomatic volunteers screened. The frequency of such tears increased from 13% in the youngest group (aged 50-59 y) to 20% (aged 60-69 y), 31% (aged 70-79 y), and 51% in the oldest group (aged 80-89 y). That such high tear prevalence was seen in asymptomatic volunteers even led Tempelhof et al⁴⁷ to suggest that rotator cuff tears could be seen within the framework of "normal" aging rather than an endpoint of an overtly pathological process.

Histological evidence supporting a degenerative cause also exists. Kannus and Jozsa²⁴ reviewed acute, subacute, and chronic cuff ruptures in 891 tendons and found evidence of degenerative change in 97% of these. Age-related changes seen in the tendon included loss of cellularity, loss of vascularity, and loss of fibrocartilage mass at the site of the cuff insertion.⁴ Such changes are typically not seen in younger individuals.²⁷ In a recent study of 80 postoperative rotator cuff specimens, Hashimoto et al²² found 7 characteristic features of age-related degeneration in the tissue specimens. In all 80 cases, they found thinning and disorientation of the collagen fibers, myxoid degeneration, and hyaline degeneration. The other degenerative changes included vascular proliferation (34%), fatty infiltration (33%), chondroid metaplasia (21%), and calcification (19%). Of these, only vascular proliferation and fatty infiltration were more common on the bursal side relative to the articular side. The authors supposed that these 2 changes reflected reparative processes, stemming from the more vascular areas of the cuff. The remaining 5 features were thought to be primarily degenerative changes contributing to a reduced tensile capacity.²⁴

Several histology studies have tried to find mediators for the changes above. A biochemical mediator for tendon retraction was postulated by Premdas et al³⁹ who found increased levels of smooth muscle actin (SMA) within the nonvascular connective tissue cells immediately surrounding torn rotator cuff edges in 7 human cuff explants. Smooth muscle actin in vitro leads to contraction of collagen-glycosaminoglycans compounds, substances found in considerable concentrations within the rotator cuff. In vivo, this may translate into SMA cells causing the damaged cuff to retract with the increasing distances at the repair margin, which results in an inhibition of healing.

Other studies have emphasized the role of altered collagen fiber quality as an important mediator of cuff degeneration.²⁷ In health, the central zone of the supraspinatus tendon is primarily composed of type I collagen with smaller amounts of type III collagen, decorin, and biglycan. In contrast, the fibrocartilaginous zone of the tendon insertion

against the humerus is primarily composed of type II collagen, a collagen subtype often associated with withstanding compressive loads. In diseased rotator cuff there is an increase in the levels of type III collagen within the fibrocartilaginous zone, a collagen subtype associated with tendon healing. There was a concurrent decrease in levels of type II collagen.²⁷ It is unclear how much of the alteration in collagen composition is an age-related degeneration, progressive injury,⁴² or a result of changing patterns of use.² Irrespective of cause, the reported change in collagen composition could plausibly reduce the tendon's ability to withstand the compressive loads traditionally associated with type II collagen.

Microtrauma Theory. Advocates of the microtrauma theory suggest that repetitive stresses lead to small injuries within the tendon that are given an insufficient time to heal before further trauma. The combination of weaker cuffs with a single traumatic insult, or progressive microtrauma, then lead to cuff tearing. These findings are consistent with the early studies of Codman⁹ that demonstrated that partial cuff tears typically began on the articular side of the tendon, because the load capacity of the bursal side is higher than that of the articular side, making the articular side more prone to damage. Typically after the deep fibers tear, they retract because they remain under tension even with the arm at rest. This results in an increased load on the remaining fibers that increases the likelihood of further rupture.³²

A repetitive microtrauma model also implies the possibility of an inflammatory component—both acutely with any injury and chronically with any reparative process. The rat animal model has been used to model repetitive overuse lesions, mirroring the repetitive motion of the supraspinatus under the acromial arch.⁴⁵ In this animal model, overuse leads to a progressive downregulation of gene expression in transforming growth factor beta-1 (TGF- β 1) and the normal collagen constituents within the rat supraspinatus tendon, consistent with what is seen in the human degeneration studies mentioned earlier.²⁷ There was also an increase in cellularity, loss of collagen orientation, and alterations in gross cell morphologic characteristics. By the end of the trial period (13 weeks), the tendons had a higher cross-sectional area and lower load-to-failure with respect to controls. In a separate study, Perry et al³⁸ looked at the inflammatory environment of the cuff in rats undergoing repetitive microtrauma injuries using reverse-transcriptase polymerase chain reaction (RT-PCR). They found acute increases in angiogenic messenger ribonucleic acid (mRNA) markers (VEGF) peaking at 3 days to roughly 400% of preprotocol levels, and subacute increases in inducible cyclo-oxygenase (COX-2), peaking to roughly 300% of normal levels at 8 weeks after initiation of the overuse protocol. Taken together, these 2 studies^{38,45} by the Soslowsky group not only support chronic overuse as an etiological factor in tendon degeneration, but also imply an important role for angiogenic and inflammatory mediators.

In vitro studies of human tendon remains the only current live human model capable of hypothesizing the response to microtrauma in the acute situation. In such cases, progressive cyclic loading of tendons ex vivo is used

to mimic the tissue injury that would occur with microtrauma in vivo. Tsuzaki et al⁴⁸ investigated the biochemical cascade of interleukin-1 beta (IL-1 β) on human tendon cells on the basis of in vivo studies that suggested it may be a proinflammatory mediator. Using semiquantitative RT-PCR, they found an increase in mRNA levels of COX-2 mirrored with an increase in tissue concentrations of prostaglandin E₂ (PGE₂). In addition, they found increased mRNA expression of matrix metalloproteinases (MMP), specifically MMP-1, MMP-3, and MMP-13, as well as non-lymphocyte tissue production of the proinflammatory cytokine IL-1 β that amplified the original exogenous cytokine delivery. While the importance of IL-1 β to cuff tears remains inconclusive in vivo,¹⁸ if true, this study supposes the painful symptoms of cuff disease are mediated via COX-2 and PGE₂, while the loss of tissue architecture is mediated by the range of MMPs released by the activated tendons. There are 2 studies that further support these conclusions. First, Koshima et al²⁶ measured the mRNA expression of the same mediators after a surgical tear of the rabbit rotator cuff and found increased concentrations of IL-1 β (peak = day 1) and COX-2 (peak = day 7) after the tear. Subsequently, Li et al²⁸ showed that in response to cyclic tensile loading, human fibroblasts release the inflammatory mediators PGE₂ and leukotriene B₄. However, while the delivery indomethacin (a cyclooxygenase inhibitor) and MK-886 (a synthetic leukotriene antagonist) reduced the levels of PGE₂ and leukotriene B₄, respectively, any reduction resulted in compensatory increases of the other mediator.

Inflammation. There are also numerous studies somewhat more equivocal about the importance of an inflammatory component in cuff disease. Histology studies notably have failed to find a significant chronic inflammatory environment in rotator cuff tears and other tendinopathies in cadaveric and postsurgical specimens.³ Some studies have noted revascularization intraoperatively²² and preoperatively via powered Doppler ultrasound,³⁷ which is broadly consistent with other chronic inflammatory conditions such as osteoarthritis.⁶ Nonetheless, the current human in vivo evidence base for a strong inflammatory component remains relatively weak.

Oxidative stress and apoptosis. Another mediator for age-related degeneration may be the accumulation of reactive oxygen species (ROS) leading to oxidative stress and increased cell apoptosis, which already has been implicated in damage to several other organ systems.¹⁰ Yuan et al⁵⁶ noted an increased proportion of apoptotic cells at the edge of a rotator cuff tear (34%) compared with controls (13%). They also demonstrated that exposure of cultured human rotator cuff tendon to oxidative stress via exogenous administration of H₂O₂ resulted in increased levels of both cytochrome-c and caspase-3 (key apoptotic mediators) within the tendon cells.⁵⁵ Further studies reported upregulation of a novel antioxidant peroxidase recently identified in mammals, peroxiredoxin 5 (PRDX5), within degenerated rotator cuff in vivo, and in response to H₂O₂ oxidative insults in vitro.⁵⁴ Overexpression of PRDX5 via transfection in cultured tendon reduced tendon apoptosis by 46% and provided a small but noticeable increase in

neocollagen synthesis. The implication from these studies is that PRDX5 not only has a protective role in human cuff degeneration, but that oxidative damage-induced apoptosis may be a significant, and possibly modifiable, contributor to rotator cuff degeneration.

If oxidative stress is indeed an important factor in tendinopathy, what could the effector mechanisms be? Two key candidates have received recent consideration—Matrix metalloproteinase-1 (MMP-1) within the extracellular matrix and c-Jun N-terminal protein kinase (JNK) within the intracellular environment. Matrix metalloproteinase-1, or its precursor, pro-MMP-1, is found in normal tendon at very low concentrations to effect the natural turnover of collagen (in particular, type I collagen, the main constituent of healthy tendon). Matrix metalloproteinase-1 concentrations are increased in damaged tendon, possibly leading to disorganized tissue architecture, reduced collagen synthesis, and weakened tendon biomechanics.¹⁷ c-Jun N-terminal protein kinase-1 is a mitogen-induced protein kinase (MAPK) that is induced in tendons by both IL-1 (a proinflammatory cytokine) and by cyclic mechanical stretch, among others.⁴⁴ When phosphorylated, the JNK family activates a number of downstream transcription factors linked to the apoptotic pathway.¹² The Murrell group⁵⁰ demonstrated that JNK and MMP-1 levels were increased in torn supraspinatus specimens in vivo, and when tendon specimens were cultured in H₂O₂, they showed increased expression of JNK1, JNK2, and MMP-1. If JNK-specific inhibitors were used, there was reduction in MMP-1 levels 8 to 24 hours later. Taken together, this implies a high-level role in the apoptotic pathway for JNK in the response to tendon injury, with MMPs being one of the downstream effectors. The cumulative effect of this activation could then have a contributory effect to tendon degeneration at a biochemical level. c-Jun N-terminal protein kinase-2 knockout mice engineered for a collagen-induced arthritis mouse model showed a reduced expression of MMP-3 and MMP-13 and a reduction in cartilage erosion, which supports the upstream role of JNK in the regulation of the extracellular matrix.¹⁹ A possible model pathway of how this may occur is illustrated in Figure 1.

Summary of Degeneration-Microtrauma Synergy

The degeneration-microtrauma model is likely to be critical in the development of cuff disease in many patients. Degeneration of rotator cuff tendon is multifaceted, and a number of studies have attempted to elucidate the biochemical pathway.^{17,19,44,50,54-56} There is evidence to support the role of inflammatory mediators and suggest that the symptoms of rotator cuff tendinopathy are mediated by COX-2 and PGE₂, and the loss of tissue architecture is mediated by the MMP. In addition, studies have also implicated oxidative stress causing tenocyte apoptosis via MMP within the extracellular matrix and JNK within the intracellular environment. On a histological evaluation, degeneration is characterized by loss of cellularity, vascularity, tissue architecture, and fibrocartilaginous mass within the

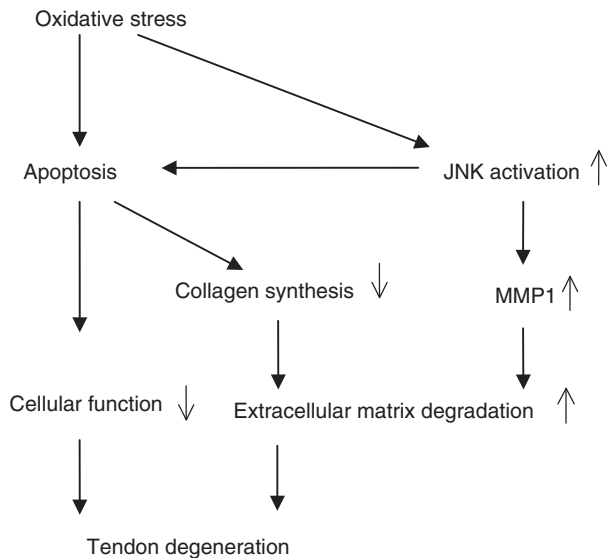


Figure 1. Rotator cuff degeneration secondary to oxidative stress and apoptosis: a possible pathway.⁵⁰

cuff resulting in a mechanically inferior tendon. This is then compounded by repetitive microtrauma—mechanical loading of degenerative tendon leading to several small tears that only partially heal until the tendon is so weakened that a full-thickness tear develops.

Cuff Vascularity

It has been traditionally taught that there exists a “critical” or hypovascular zone 10 to 15 mm proximal to the insertion of the supraspinatus tendon,²⁹ but these assertions have increasingly become an area of controversy. Moseley and Goldie³⁴ examined capillary distributions in cuff specimens and concluded that no hypovascular areas exist. Brooks et al⁷ determined that both vessel diameter and number were approximately reduced by a third just 5 mm from the cuff edge compared with 30 mm from the edge, but determined no significantly hypovascular areas exist. They concluded that hypovascularity was a minimal contributor, if at all, to cuff tears.

Indeed, in torn rotator cuff tendons, histologic and immunohistochemical analyses have reported relative hyperperfusion at the area of the critical zone.¹⁴ This has been supported by intraoperative laser Doppler flowmetry that showed no hypoperfusion in vivo and hyperperfusion at the tear edge.⁴⁶ The hypervascularity in such cases is thought to come from proliferation in the subsynovial layer in response to injury.⁴⁹ Taken together, these data have cast considerable doubt on the importance of the “critical zone” in supraspinatus lesions.

Despite this, a possible role for hypovascularity may still remain. This stems from the observation that perfusion within the rotator cuff is a dynamic phenomenon, with markedly reduced perfusion when the arm is in full adduction.⁴⁰ In situations with supraspinatus compressed at the

humeral head, it is possible that avascularity may be a contributory factor.

Fealy et al¹¹ conducted a study to assess the vascular pattern after rotator cuff repair compared with a group of asymptomatic controls. They determined that after surgery, the repaired rotator cuff experiences a robust vascular response, particularly in the peritendinous region, that decreases predictably over time.¹¹ The study provides evidence that rotator cuff blood flow has the potential to change with implications of increasing the recruitment of blood flow as an adjuvant either before or after surgery.

Neural Theory of Tendinopathy

Molloy et al³³ performed a microarray analysis of the supraspinatus tendon in the rat after overuse and found increased expression of a range of glutamate-signaling proteins. They went on to culture tendons in glutamate and found an increase in apoptotic frequency. Glutamate, a peptide normally associated with central nervous system (CNS) signaling, has already been extensively implicated in the pathogenesis of Achilles tendinopathy.¹ Together with Substance P (recently found in increased concentrations in diseased rotator cuff¹⁶), it is now also implicated in the emerging “neural” theory of tendinopathy.⁴¹ This theory proposes that neural overstimulation in response to overuse leads to a recruitment of inflammatory cells, a phenomenon already noted in vivo.²¹ This recruitment could then lead to painful symptoms as well as reorganization of rotator cuff architecture, leading to structural weakness and cuff damage. In addition, the repeated stimulation could result in an “excitotoxic” reaction within the tendon leading to apoptosis, similar to what is seen with glutamate-induced apoptosis of CNS neurons.³³ Although clearly speculative, such a theory remains an exciting vein of study for future research.

CONCLUSION

Emerging scientific studies have elucidated the complex process of rotator cuff degeneration. There are a number of theories implicated in rotator cuff degeneration leading to full-thickness tears. Acromial shape in particular probably contributes to bursal-sided rotator cuff tears. More commonly, rotator cuff tears are thought to begin on the articular side in the setting of age-related degeneration and repetitive microtrauma. In the degeneration-microtrauma model, an inflammatory process causes changes in the local milieu, which alters tendon gene expression and histopathology. Additionally, oxidative stress leads to tenocyte apoptosis via the JNK-MMP pathway and likely contributes to further tendon degeneration. The more recent neural theory suggests that overuse causes neural overstimulation and may also contribute to the painful symptoms as well as local inflammation and apoptosis. The repetitive loads on the degenerative rotator cuff leads to a vicious circle such that partial-thickness and eventually full-thickness rotator cuff tears develop. With an improved understanding of tendon degeneration, potential therapeutic modalities may be developed for the treatment of rotator cuff tendinopathy.

The search for potentially modifiable mediators for these changes is difficult, but several candidates have been proposed. Inflammatory and apoptotic pathways may be particularly significant in this regard. A number of "low-level" mediators have been demonstrated in animal models and human ex vivo models. These include arachidonic acid metabolites (prostaglandins, leukotrienes), MMPs, tissue protein kinases (such as c-JNK), apoptotic mediators (caspases, cytochrome-c), and reactive oxygen species. This in turn may lead to a number of "high-level" targets for pharmacological intervention: cyclo-oxygenase (responsible for prostaglandin synthesis) through the use of nonsteroidal anti-inflammatory drugs; phospholipase A-2 (responsible for all arachidonic acid metabolites) through corticosteroids; cytokines such as IL-1 β again through corticosteroids; and antioxidants to "mop up" the proapoptotic reactive oxygen species. These may be delivered systemically or locally, similar in principal to tacrolimus-eluting stents in coronary artery disease. However, the evidence for such agents is lacking, and further study of these processes will be needed before they can be reasonably incorporated into biologic interventions.

REFERENCES

- Alfredson H, Thorsen K, Lorentzon R. In situ microdialysis in tendon tissue: high levels of glutamate, but not prostaglandin E₂ in chronic Achilles tendon pain. *Knee Surg Sports Traumatol Arthrosc.* 1999;7(6):378-381.
- Amiel D, Akeson WH, Harwood FL, Mechanic GL. The effect of immobilization on the types of collagen synthesized in periarticular connective tissue. *Connect Tissue Res.* 1980;8(1):27-32.
- Astrom M, Rausing A. Chronic Achilles tendinopathy. A survey of surgical and histopathologic findings. *Clin Orthop Relat Res.* 1995;316:151-164.
- Barr KP. Rotator cuff disease. *Phys Med Rehabil Clin N Am.* 2004;15(2):475-491.
- Bigliani L, Morrison D, April E. The morphology of the acromion and rotator cuff impingement. *Orthop Trans.* 1986;10:228.
- Bonnet CS, Walsh DA. Osteoarthritis, angiogenesis, and inflammation. *Rheumatology (Oxford).* 2005;44(1):7-16.
- Brooks CH, Revell WJ, Heatley FW. A quantitative histological study of the vascularity of the rotator cuff tendon. *J Bone Joint Surg Br.* 1992;74:151-153.
- Chen AL, Shapiro JA, Ahn AK, Zuckerman JD, Cuomo F. Rotator cuff repair in patients with type I diabetes mellitus. *J Shoulder Elbow Surg.* 2003;12(5):416-421.
- Codman EA. *The Shoulder: Rupture of the Supraspinatus Tendon and Other Lesions in or About the Subacromial Bursa.* Boston, Mass: Thomas Todd; 1934.
- Droge W. Oxidative stress and aging. *Adv Exp Med Biol.* 2003;543:191-200.
- Fealy S, Adler RS, Drakos MC, et al. Patterns of vascular and anatomical response after rotator cuff repair. *Am J Sports Med.* 2006;34(1):120-127.
- Filomeni G, Aquilano K, Civitareale P, Rotilio G, Ciriolo MR. Activation of c-Jun-N-terminal kinase is required for apoptosis triggered by glutathione disulfide in neuroblastoma cells. *Free Radic Biol Med.* 2005;39(3):345-354.
- Flatow EL, Weinstein DM, Duralde XA, Compito CA, Pollack RG, Bigliani LU. Coracoacromial ligament preservation in rotator cuff surgery. *J Shoulder Elbow Surg.* 1994;3(Suppl):S73.
- Fukuda H, Hamada K, Yamanaka K. Pathology and pathogenesis of bursal-side rotator cuff tears viewed from en bloc histologic sections. *Clin Orthop Relat Res.* 1990;254:75-80.
- Galatz LM, Silva MJ, Rothermich SY, Zaegel MA, Havlioglu N, Thomopoulos S. Nicotine delays tendon-to-bone healing in a rat shoulder model. *J Bone Joint Surg Am.* 2006;88(9):2027-2034.
- Gotoh M, Hamada K, Yamakawa H, Inoue A, Fukuda H. Increased substance P in subacromial bursa and shoulder pain in rotator cuff diseases. *J Orthop Res.* 1998;16(5):618-621.
- Gotoh M, Hamada K, Yamakawa H, Tomonaga A, Inoue A, Fukuda H. Significance of granulation tissue in torn supraspinatus insertions: an immunohistochemical study with antibodies against interleukin-1 β , cathepsin D, and matrix metalloproteinase-1. *J Orthop Res.* 1997;15(1):33-39.
- Gotoh M, Hamada K, Yamakawa H, et al. Interleukin-1-induced glenohumeral synovitis and shoulder pain in rotator cuff diseases. *J Orthop Res.* 2002;20(6):1365-1371.
- Han Z, Boyle DL, Chang L, et al. c-Jun N-terminal kinase is required for metalloproteinase expression and joint destruction in inflammatory arthritis. *J Clin Invest.* 2001;108(1):73-81.
- Harryman DT 2nd, Hettrich CM, Smith KL, Campbell B, Sidles JA, Matsen FA 3rd. A prospective multipractice investigation of patients with full-thickness rotator cuff tears: the importance of comorbidities, practice and other covariables on self-assessed shoulder function and health status. *J Bone Joint Surg Am.* 2003;85(4):690-696.
- Hart DA, Frank CB, Bray RC. Inflammatory processes in repetitive motion and overuse syndromes: potential role of neurogenic mechanisms in tendons and ligaments. In: Gordon SL, Blair SJ, and Fine L J, eds. *Repetitive Motion Disorders of the Upper Extremity.* Rosemont, Ill: American Academy of Orthopaedic Surgeons; 1995:247-262.
- Hashimoto T, Nobuhara K, Hamada T. Pathologic evidence of degeneration as a primary cause of rotator cuff tear. *Clin Orthop Relat Res.* 2003;415:111-120.
- Hyvonen P, Lohi S, Jalovaara P. Open acromioplasty does not prevent the progression of an impingement syndrome to a tear. Nine-year follow-up of 96 cases. *J Bone Joint Surg Br.* 1998;80(5):813-816.
- Kannus P, Jozsa L. Histopathological changes preceding spontaneous rupture of a tendon. A controlled study of 891 patients. *J Bone Joint Surg Am.* 1991;73(10):1507-1525.
- Ko JY, Huang CC, Chen WJ, Chen CE, Chen SH, Wang CJ. Pathogenesis of partial tear of the rotator cuff: a clinical and pathologic study. *J Shoulder Elbow Surg.* 2006;15(3):271-278.
- Koshima H, Kondo S, Mishima S, et al. Expression of interleukin-1 β , cyclo-oxygenase-2, and prostaglandin E₂ in a rotator cuff tear in rabbits. *J Orthop Res.* 2007;25(1):92-97.
- Kumagai J, Sarkar K, Uthoff HK. The collagen types in the attachment zone of rotator cuff tendons in the elderly: an immunohistochemical study. *J Rheumatol.* 1994;21(11):2096-2100.
- Li Z, Yang G, Khan M, Stone D, Woo SL, Wang JH. Inflammatory response of human tendon fibroblasts to cyclic mechanical stretching. *Am J Sports Med.* 2004;32(2):435-440.
- Lohr JF, Uthoff HK. The microvascular pattern of the supraspinatus tendon. *Clin Orthop Relat Res.* 1990;254:35-38.
- MacGillivray JD, Fealy S, Potter HG, O'Brien SJ. Multiplanar analysis of acromion morphology. *Am J Sports Med.* 1998;26(6):836-840.
- Mallon WJ, Misamore G, Sneed DS, Denton P. The impact of preoperative smoking habits on the results of rotator cuff repair. *J Shoulder Elbow Surg.* 2004;13(2):129-132.
- Matsen FA 3rd. Rotator cuff. In: Rockwood CA Jr, Matsen FA 3rd, eds. *The Shoulder.* Philadelphia, PA: W B Saunders; 1998:755-839.
- Molloy TJ, Kemp MW, Wang Y, Murrell GA. Microarray analysis of the tendinopathic rat supraspinatus tendon: glutamate signaling and its potential role in tendon degeneration. *J Appl Physiol.* 2006;101(6):1702-1709.
- Moseley HF, Goldie I. The arterial pattern of the rotator cuff of the shoulder. *J Bone Joint Surg Br.* 1963;45:780-789.
- Neer CS, Poppen NK. Supraspinatus outlet. *Orthop Trans.* 1987;11: 234.
- Nicholson GP, Goodman DA, Flatow EL, Bigliani LU. The acromion: morphologic condition and age-related changes. A study of 420 scapulas. *J Shoulder Elbow Surg.* 1996;5(1):1-11.

37. Ohberg L, Lorentzon R, Alfredson H. Neovascularisation in Achilles tendons with painful tendinosis but not in normal tendons: an ultrasonographic investigation. *Knee Surg Sports Traumatol Arthrosc.* 2001;9(4):233-238.
38. Perry SM, McIlhenny SE, Hoffman MC, Soslowky LJ. Inflammatory and angiogenic mRNA levels are altered in a supraspinatus tendon overuse animal model. *J Shoulder Elbow Surg.* 2005;14(1 Suppl S):79S-83S.
39. Premdas J, Tang JB, Warner JP, Murray MM, Spector M. The presence of smooth muscle actin in fibroblasts in the torn human rotator cuff. *J Orthop Res.* 2001;19(2):221-228.
40. Rathbun JB, Macnab I. The microvascular pattern of the rotator cuff. *J Bone Joint Surg Br.* 1970;52(3):540-553.
41. Rees JD, Wilson AM, Wolman RL. Current concepts in the management of tendon disorders. *Rheumatology (Oxford).* 2006;45(5):508-521.
42. Riley GP, Harrall RL, Constant CR, Chard MD, Cawston TE, Hazleman BL. Tendon degeneration and chronic shoulder pain: changes in the collagen composition of the human rotator cuff tendons in rotator cuff tendinitis. *Ann Rheum Dis.* 1994;53(6):359-366.
43. Shah NN, Bayliss NC, Malcolm A. Shape of the acromion: congenital or acquired—a macroscopic, radiographic, and microscopic study of acromion. *J Shoulder Elbow Surg.* 2001;10(4):309-316.
44. Skutek M, van Griensven M, Zeichen J, Brauer N, Bosch U. Cyclic mechanical stretching of human patellar tendon fibroblasts: activation of JNK and modulation of apoptosis. *Knee Surg Sports Traumatol Arthrosc.* 2003;11(2):122-129.
45. Soslowky LJ, Thomopoulos S, Tun S, et al. Neer Award 1999. Overuse activity injures the supraspinatus tendon in an animal model: a histologic and biomechanical study. *J Shoulder Elbow Surg.* 2000;9(2):79-84.
46. Swiontkowski MF, Iannotti JP, Boulas HJ, Esterhai JL. Intraoperative assessment of rotator cuff vascularity using laser Doppler flowmetry. In: Post M, Morrey BF, Hawkins RJ, eds. *Surgery of the Shoulder.* St. Louis, Mo: Mosby; 1990:208-212.
47. Tempelhof S, Rupp S, Seil R. Age-related prevalence of rotator cuff tears in asymptomatic shoulders. *J Shoulder Elbow Surg.* 1999; 8(4):296-299.
48. Tsuzaki M, Guyton G, Garrett W, et al. IL-1 beta induces COX2, MMP-1, -3, and -13, ADAMTS-4, IL-1 beta and IL-6 in human tendon cells. *J Orthop Res.* 2003;21(2): 256-264.
49. Unthoff HK, Kumagi J, Sarkar K. Morphologic evidence of healing in torn human rotator cuffs. *J Bone Joint Surg Br.* 1992;74(suppl 3):293-294.
50. Wang F, Murrell GA, Wang MX. Oxidative stress-induced c-Jun N-terminal kinase (JNK) activation in tendon cells upregulates MMP1 mRNA and protein expression. *J Orthop Res.* 2007;25(3):378-389.
51. Wang JC, Horner G, Brown ED, Shapiro MS. The relationship between acromial morphology and conservative treatment of patients with impingement syndrome. *Orthopedics.* 2000;23(6):557-559.
52. Wang JC, Shapiro MS. Changes in acromial morphology with age. *J Shoulder Elbow Surg.* 1997;6(1):55-59.
53. Yamaguchi K, Ditsios K, Middleton WD, Hildebolt CF, Galatz LM, Teefey SA. The demographic and morphological features of rotator cuff disease. A comparison of asymptomatic and symptomatic shoulders. *J Bone Joint Surg Am.* 2006;88(8):1699-1704.
54. Yuan J, Murrell GA, Trickett A, Landtmeiers M, Knoops B, Wang MX. Overexpression of antioxidant enzyme peroxiredoxin 5 protects human tendon cells against apoptosis and loss of cellular function during oxidative stress. *Biochim Biophys Acta.* 2004;1693(1):37-45.
55. Yuan J, Murrell GA, Trickett A, Wang MX. Involvement of cytochrome c release and caspase-3 activation in the oxidative stress-induced apoptosis in human tendon fibroblasts. *Biochim Biophys Acta.* 2003;1641(1):35-41.
56. Yuan J, Murrell GA, Wei AQ, Wang MX. Apoptosis in rotator cuff tendonopathy. *J Orthop Res.* 2002;20(6):1372-1379.